

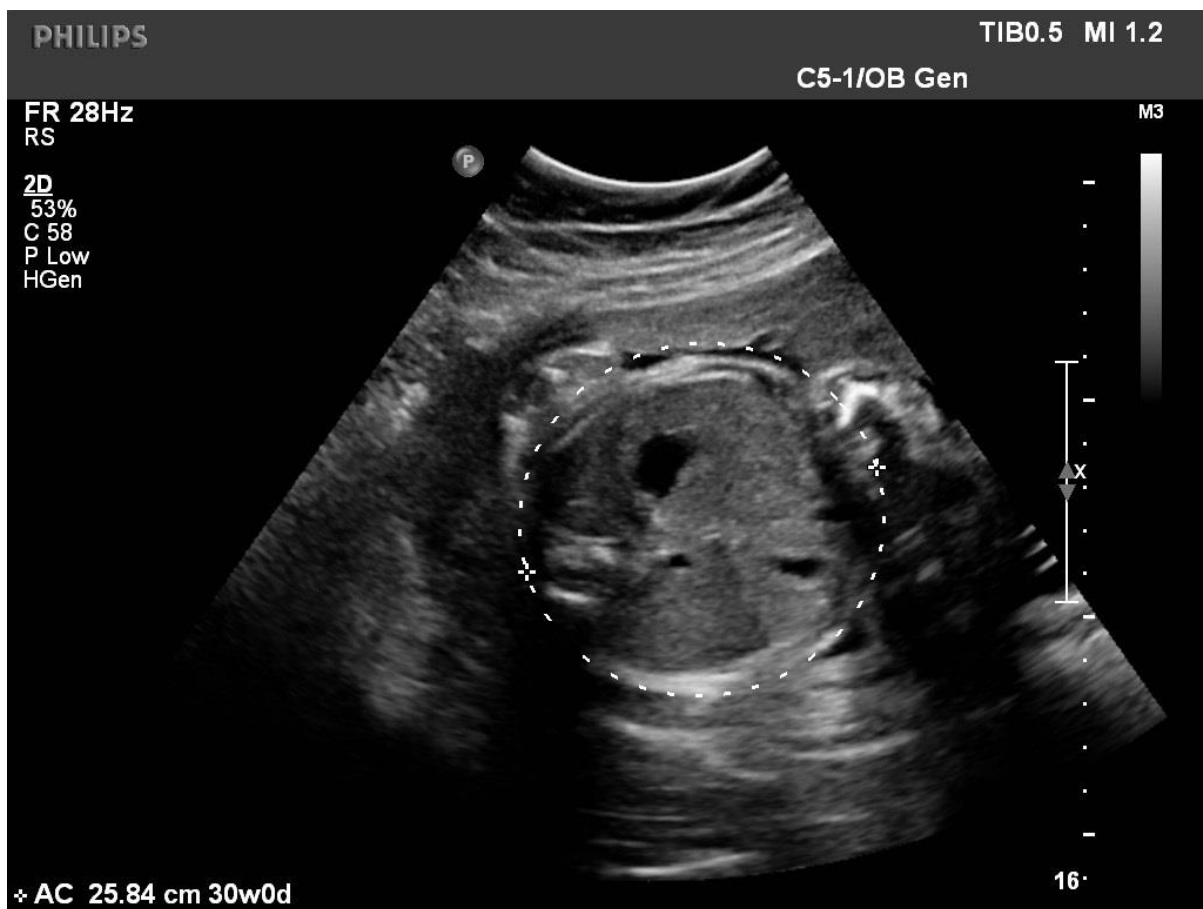Image Critique Assessment – Month 2

In the 'Obstetric and gynaecologic ultrasound curriculum and competency assessment in residency training programs: consensus report' (attached on the Phase II webpage) the following image criteria are listed as one level of competency:

- A. Mean sac diameter
- B. Crown–rump length
- C. Fetal presentation
- D. Fetal extremities
- E. Biparietal diameter
- F. Head circumference
- G. Abdominal circumference
- H. Femur diaphysis length
- I. Biophysical profile (ultrasound components)
- J. Amniotic fluid index K. Maximum vertical pocket

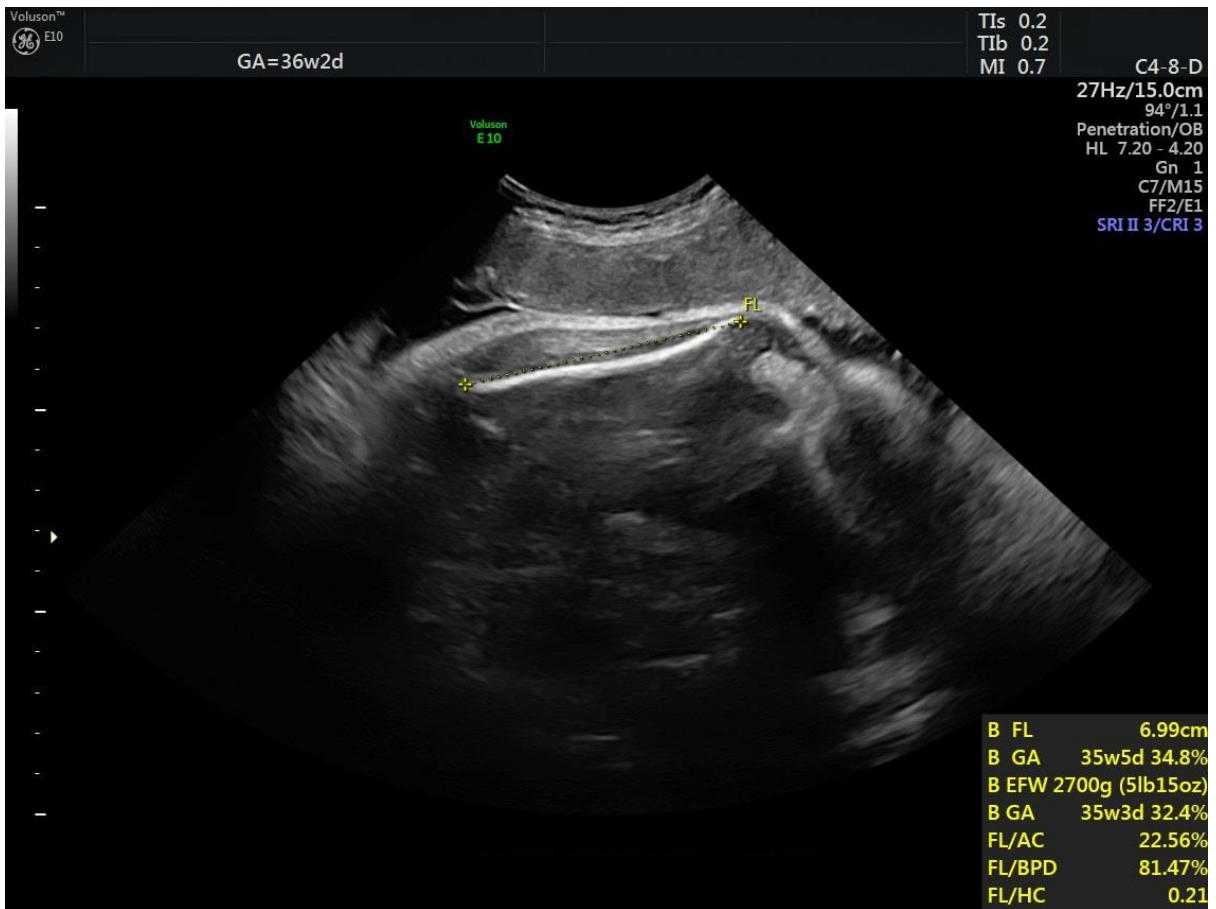
The following assessment provides images from this level of competency for you to assess. Please provide feedback for each image in the box provide underneath the image. This feedback will be assessed by your virtual mentor who will support you in improving your image critiquing.

Abdominal Circumference



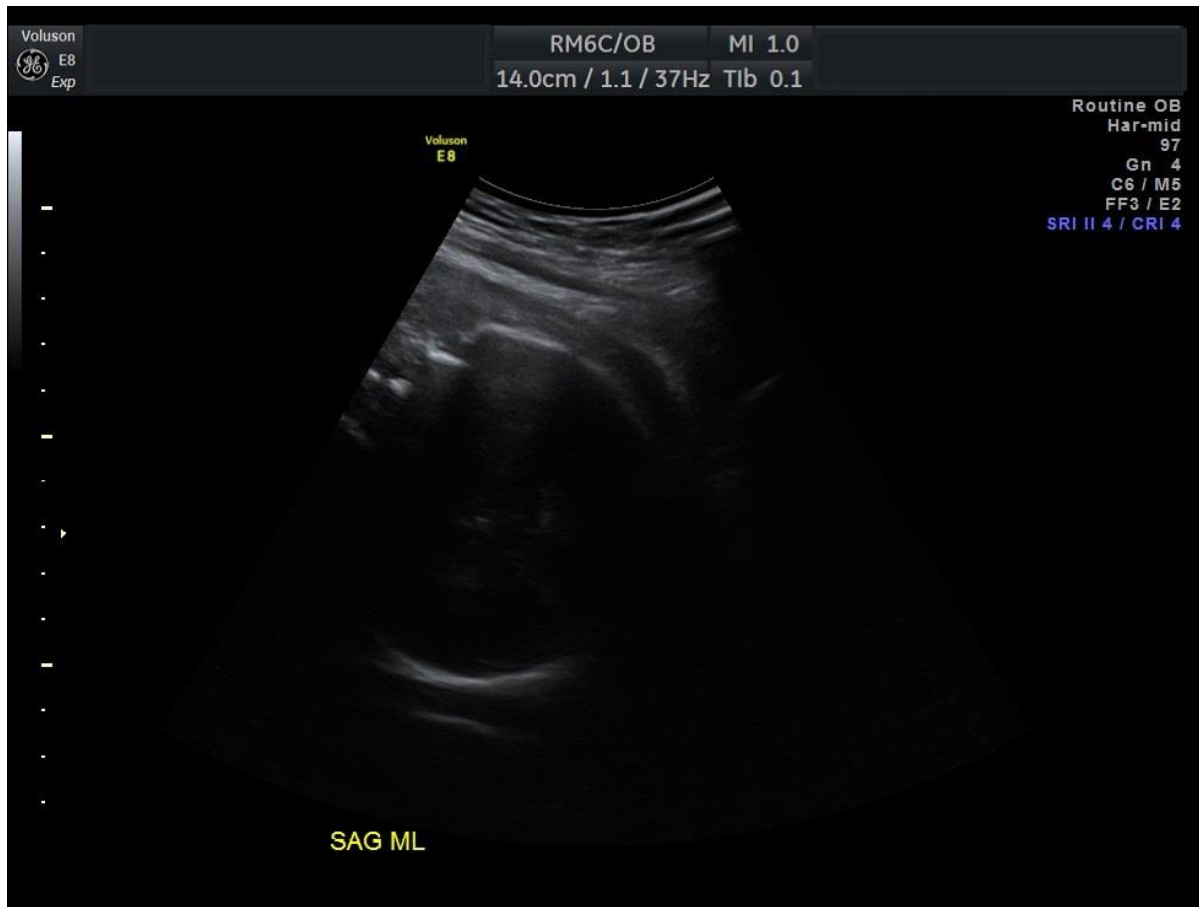[Provide feedback for the image here]

Femur Length



[Provide feedback for the image here]

Fetal Presentation



[Provide feedback for the image here]