

Fetal sonographic diagnosis of aortic arch anomalies

S.-J. YOO*†, J.-Y. MIN‡, Y.-H. LEE‡, K. ROMAN*†, E. JAEGGI† and J. SMALLHORN†

*Department of Diagnostic Imaging, †Division of Cardiology, Department of Pediatrics, Hospital for Sick Children, University of Toronto, Toronto, Canada and ‡Department of Radiology, Samsung Cheil Hospital, Sungkyunkwan University School of Medicine, Seoul, Korea

KEYWORDS: aortic arch anomaly; diverticulum of Kommerell; fetus

ABSTRACT

Aortic arch anomalies refer to congenital abnormalities of the position or branching pattern, or both of the aortic arch. Although aortic arch anomalies are not uncommon, reports on their prenatal diagnosis are scarce. Insight into the hypothetical arch model is crucial to understanding anomalies of the aortic arch in the fetus. Recognition of the trachea, three major vessels, ductus arteriosus and descending aorta in the axial views of the upper mediastinum is necessary for a complete fetal cardiac assessment. Clues to aortic arch anomalies include abnormal position of the descending aorta, absence of the normal 'V'-shaped confluence of the ductal and aortic arches, a gap between the ascending aorta and main pulmonary artery in the three-vessel view, and an abnormal vessel behind the trachea with or without a vascular loop or ring around the trachea. Meticulous attention to anatomic landmarks will lead to successful prenatal diagnosis of important vascular rings making early postnatal management possible. Copyright © 2003 ISUOG. Published by John Wiley & Sons, Ltd.

INTRODUCTION

Aortic arch anomalies refer to a variety of congenital abnormalities of the position or branching pattern, or both, of the aortic arch (Table 1)^{1–4}. While certain patterns of aortic arch anomalies are simple positional abnormalities, there are other patterns that form a complete or incomplete vascular ring around the trachea and esophagus causing compression of the latter structures. Aortic arch anomalies may lead to respiratory distress in the neonate or the development of milder symptoms and signs of tracheal or esophageal compression later in life, or they may remain clinically silent. Aortic arch anomalies are often associated with other congenital cardiac defects or chromosomal

anomalies, such as microdeletion of chromosome 22, although they may occur in isolation. The incidences of various forms of aortic arch anomalies vary significantly among reported series.

Although aortic arch anomalies are not uncommon, there are few reports on their prenatal diagnosis^{5–8}. In a recent issue of *Ultrasound in Obstetrics and Gynecology*, Achiron and colleagues published a large series of fetuses with aortic arch anomalies⁹. In this pictorial essay we aim to illustrate the fetal sonographic features of aortic arch anomalies in association with the developmental mechanisms and fetal circulation.

HYPOTHETICAL DOUBLE AORTIC ARCH MODEL

Normal and abnormal development of the aortic arch may easily be understood by reference to the

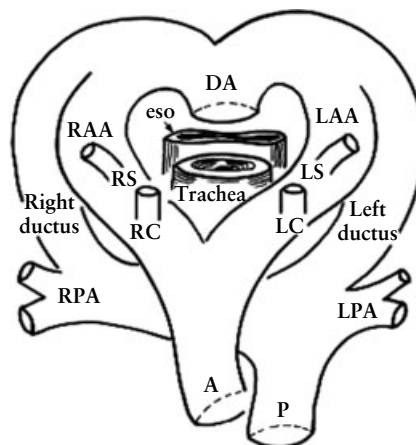


Figure 1 Hypothetical double aortic arch model of Jesse E. Edwards. A, ascending (ventral) aorta; DA, descending (dorsal) aorta; eso, esophagus; LAA, left aortic arch; LC, left common carotid artery; LPA, left pulmonary artery; LS, left subclavian artery; P, main pulmonary artery; RAA, right aortic arch; RC, right common carotid artery; RPA, right pulmonary artery; RS, right subclavian artery.

Correspondence to: Dr S.-J. Yoo, Department of Diagnostic Imaging, Hospital for Sick Children, University of Toronto, 555 University Avenue, Ontario, Toronto M5G 1X8, Canada (e-mail: shi-joon.yoo@sickkids.ca)

Accepted: 4 August 2003

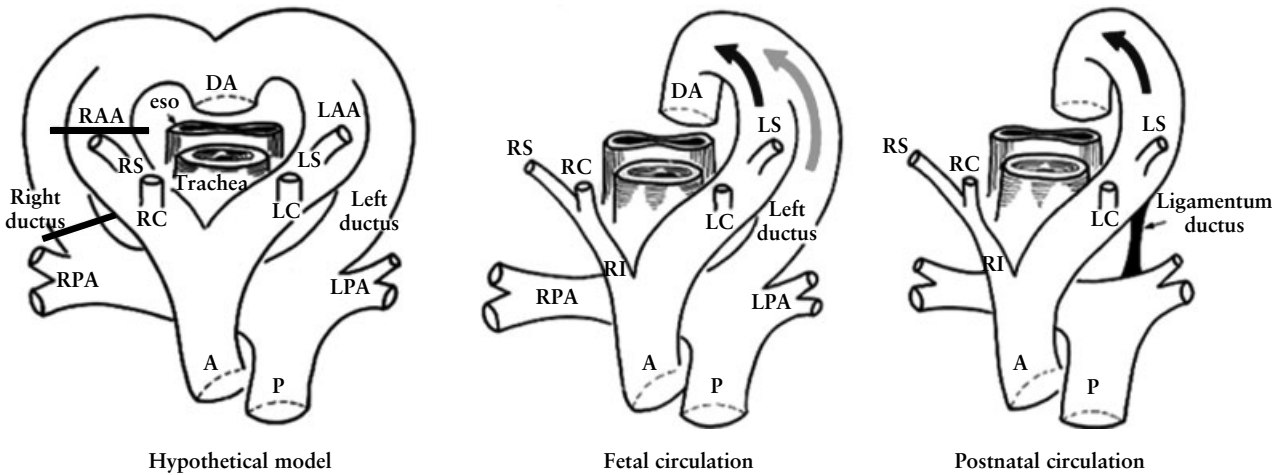


Figure 2 Developmental model of normal left aortic arch with left ductus arteriosus. Black bars in left-hand diagram indicate the segments that regress. Fetal circulation is characterized by confluence of the blood flow through the ascending aorta (black arrow) and the blood flow through the left ductus arteriosus (gray arrow). Postnatally the left ductus remains as the ligamentum arteriosum with closure of its lumen. A, ascending (ventral) aorta; DA, descending (dorsal) aorta; eso, esophagus; LAA, left aortic arch; LC, left common carotid artery; LPA, left pulmonary artery; LS, left subclavian artery; P, main pulmonary artery; RAA, right aortic arch, RC, right common carotid artery; RI, right innominate artery; RPA, right pulmonary artery; RS, right subclavian artery.

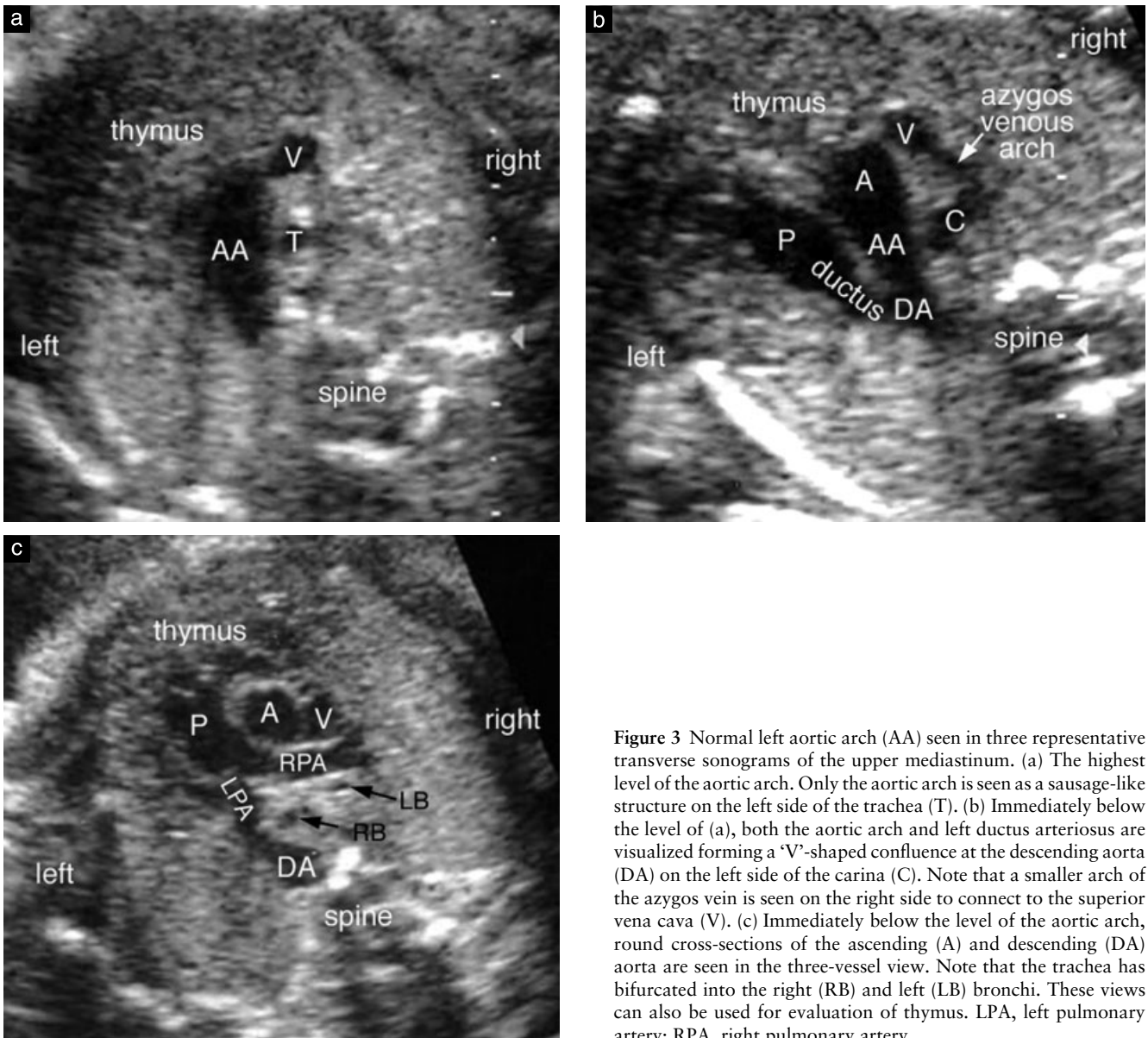

Figure 3 Normal left aortic arch (AA) seen in three representative transverse sonograms of the upper mediastinum. (a) The highest level of the aortic arch. Only the aortic arch is seen as a sausage-like structure on the left side of the trachea (T). (b) Immediately below the level of (a), both the aortic arch and left ductus arteriosus are visualized forming a 'V'-shaped confluence at the descending aorta (DA) on the left side of the carina (C). Note that a smaller arch of the azygos vein is seen on the right side to connect to the superior vena cava (V). (c) Immediately below the level of the aortic arch, round cross-sections of the ascending (A) and descending (DA) aorta are seen in the three-vessel view. Note that the trachea has bifurcated into the right (RB) and left (LB) bronchi. These views can also be used for evaluation of thymus. LPA, left pulmonary artery; RPA, right pulmonary artery.

Table 1 List of aortic arch anomalies

Aortic arch anomaly	Ring
Right AA with mirror-image branching	
With left ductus from the innominate artery	No
With right ductus from the aorta	No
Right AA with an aberrant left subclavian or innominate artery	
With left ductus from the aberrant artery	Complete
With right ductus from the aorta	Incomplete
Left AA with an aberrant right subclavian or innominate artery	
With left ductus from the aorta	Incomplete
With right ductus from the aberrant artery	Complete
Double AA	
With left ductus	Complete
With right ductus	Complete
Circumflex retroesophageal AA	Complete or incomplete
Cervical AA	
Double-lumen AA (persistent fifth AA)	

AA, aortic arch; ductus, ductus arteriosus.

hypothetical double aortic arch model described by Dr Jesse E. Edwards (Figure 1)^{4,10,11}. The model illustrates a fairly late stage of development in that the aortic sac has been divided into the ascending aorta and pulmonary arterial trunk, and the descending aorta occupies a neutral position posterior to the trachea and esophagus. On each side of the trachea and esophagus, an aortic arch connects the ascending aorta to the descending aorta, and a ductus arteriosus (ductus) connects the ipsilateral pulmonary artery to the descending aorta. The former is considered to originate from the fourth arch, while the latter together with the proximal part of the branch pulmonary artery from the sixth arch. Each aortic arch gives rise to a common carotid artery and a subclavian artery. Normally, the left aortic arch and left ductus persist, and the right arch distal to the origin of the right subclavian artery and the right ductus regress (Figure 2). Most of the aortic arch anomalies are assumed to result from abnormal persistence of a part or parts that should have regressed and/or abnormal regression of a part or parts that should have persisted.

FETAL SONOGRAPHIC APPROACH AND NORMAL ANATOMY

The left- or right-sidedness of the aortic arch refers to the position of the aortic arch relative to the trachea. It does not refer to which side of the midline the aorta ascends². The left- and right-sidedness of the ductus can also be defined by its position relative to the trachea. As we^{6,7} and Achiron *et al.*⁹ have shown, location of the aortic arch in relation to the trachea is possible because the fetal airway is normally filled with fluid allowing sonographic visualization. It can be best achieved by obtaining the orthogonal transverse views of the upper mediastinum (Figure 3a–c). We start our examination of the aortic arch from the three-vessel view¹² where the ascending

and descending aorta and main pulmonary trunk can be identified. Then, we move the transducer cephalad along the vertical axis of the fetal thorax until the aortic arch and the ductus arising from the pulmonary trunk form, on the left side of distal trachea, a 'V'- or 'Y'-shaped confluence at the descending aorta. Yagel *et al.*¹³ designated this particular plane a three vessels and trachea (3VT) view. When the transducer is moved further cephalad, only the aortic arch is seen as a sausage-shaped structure on the left side of the trachea. In these views, the descending aorta is located at the left anterior corner of the spine, and there is no vascular structure crossing the midline behind the trachea. Any branch coursing behind the trachea should be considered as an abnormal aberrant branch. Anatomical delineation of the aortic arch, its branches and ductal arch can be facilitated by using color and power Doppler examination¹⁴. The position of the aortic arch relative to the trachea can also be evaluated in a slanted coronal plane through the tracheal bifurcation (Figure 4). In this plane the cross-section of the aortic arch is seen on the left side of the trachea above the left main bronchus. The proximal left pulmonary artery or ductus is seen lateral and slightly inferior to the aortic arch. When investigating the aortic arch it is important to obtain an oblique sagittal view of the aortic arch to confirm that it gives rise to the branches to the head and neck (Figure 5). Visualization of the oblique sagittal views of the aortic arch and ductal arch can be facilitated by referencing the three-vessel or 3VT plane^{6,7}. For the aortic arch view, the transducer head is positioned so that the ascending aorta and the descending aorta are aligned with the sonographic beam axis in the three-vessel plane. Then, the transducer is rotated 90° and

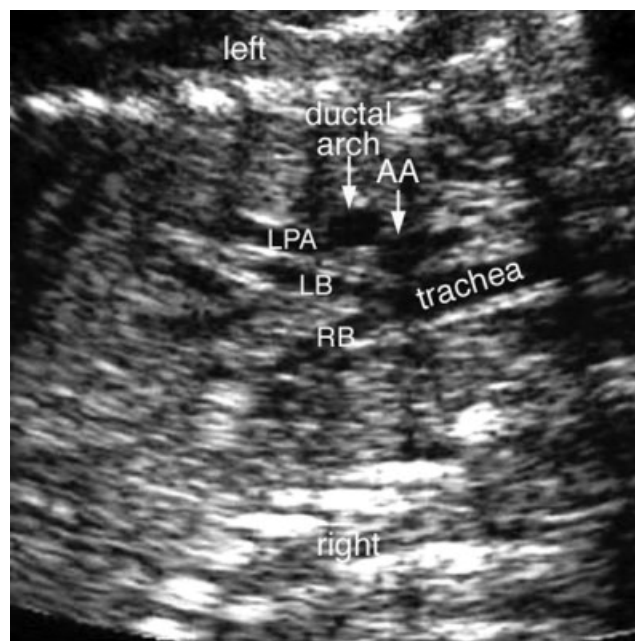


Figure 4 Coronal sonogram of the chest showing bifurcation of the trachea into the right (RB) and left (LB) main bronchi. Both aortic arch (AA) and ductal arch are seen on the left side of the trachea in this normal fetus. LPA, descending branch of the left pulmonary artery.

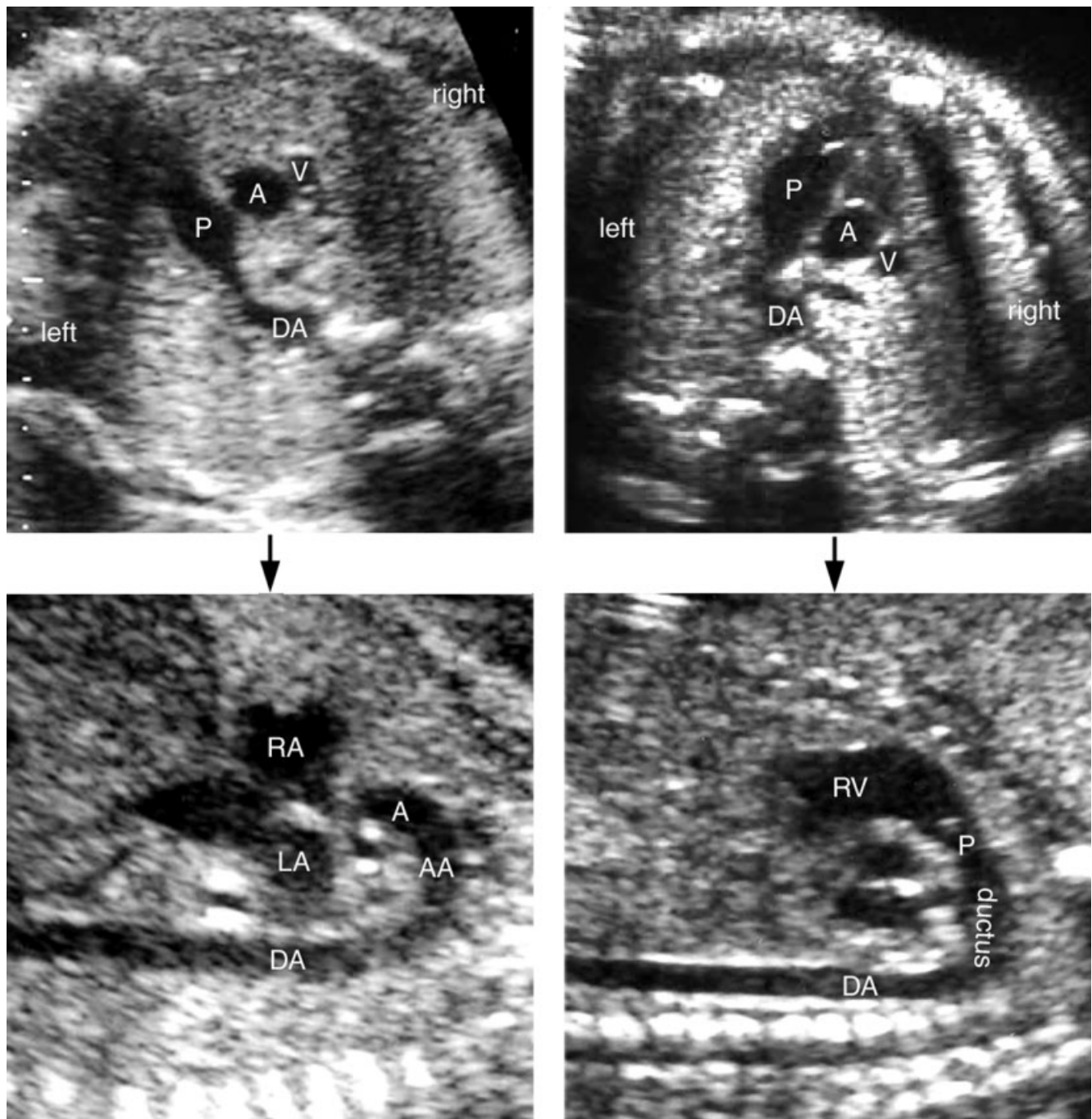


Figure 5 Maneuvers for visualization of the long-axis views of the aortic and ductal arches. For the aortic arch (AA), a three-vessel view is obtained so that the ascending aorta (A) and descending aorta (DA) are aligned vertically with the sonographic beam axis (left upper panel). Then the transducer is rotated 90°. The aortic arch is shown as a candy cane-shaped structure arising from the junction of the right (RA) and left (LA) atria (left lower panel). Note the head and neck branches of the aortic arch. For the ductal arch, a three-vessel view is obtained so that the main pulmonary artery (P) and descending aorta are aligned vertically with the sonographic beam axis (right upper panel). Then the transducer is rotated 90°. The ductal arch is shown as a hockey stick-shaped structure that is a continuation of the main pulmonary artery that arises from the right ventricle (RV). It does not give rise to any head and neck branches.

the aortic arch is seen as a candy cane-shaped structure arising from the center of the mediastinum between the right and left atria and giving rise to the head and neck branches. For the ductal arch view, a three-vessel view is obtained with the pulmonary trunk and the descending aorta aligned with the sonographic beam. From this position the transducer is rotated 90° and the ductal arch appears as a hockey stick-shaped structure arising

from the anterior mediastinum immediately behind the anterior chest wall.

RIGHT AORTIC ARCH WITH MIRROR-IMAGE BRANCHING

The most common arch anomaly in pediatric patients is a right aortic arch that gives rise to the left innominate, right

carotid and right subclavian arteries in sequence, which is a mirror-image of a normal left aortic arch. This variant is formed with regression of the left aortic arch distal to the origin of the left subclavian artery (Figure 6). Conversely, the ductus is not mirror-imaged in most cases. Usually a left ductus, instead of a right ductus, is patent¹⁻⁴. This type does not form a vascular ring or sling. It is almost always associated with congenital heart disease, most commonly tetralogy of Fallot with or without pulmonary atresia.

The diagnosis of a right aortic arch can be made in a transverse view in which a sausage-shaped aortic arch is located to the right of the trachea (Figure 7).

The clue to the diagnosis is also present in three-vessel and four-chamber views in which the descending aorta is seen on the right side or in the midline, although this finding can also be seen in double aortic arch and circumflex retroesophageal aortic arch. As the ascending aorta courses to the right in the upper mediastinum, a three-vessel view shows a gap between the ascending aorta and the main pulmonary artery. In contrast to the normal left aortic arch, the right aortic arch does not form a 'V'-shaped confluence with the ductus because the patent ductus is usually a left ductus between the left innominate artery and the left pulmonary artery. Even if the ductus is patent on the right side, the confluence of

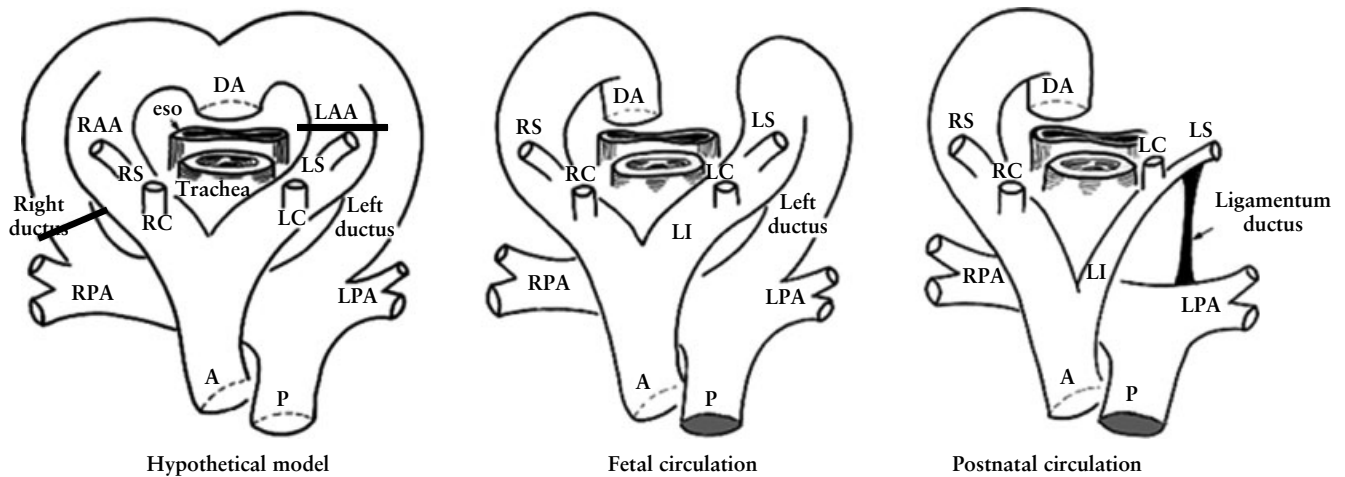


Figure 6 Developmental model of right aortic arch with mirror-image branching pattern. The black bars in the left-hand diagram indicate the segments that regress. Usually the left ductus persists. A, ascending (ventral) aorta; DA, descending (dorsal) aorta; eso, esophagus; LAA, left aortic arch; LC, left common carotid artery; LI, left innominate artery; LPA, left pulmonary artery; LS, left subclavian artery; P, main pulmonary artery; RAA, right aortic arch, RC, right common carotid artery; RPA, right pulmonary artery; RS, right subclavian artery.

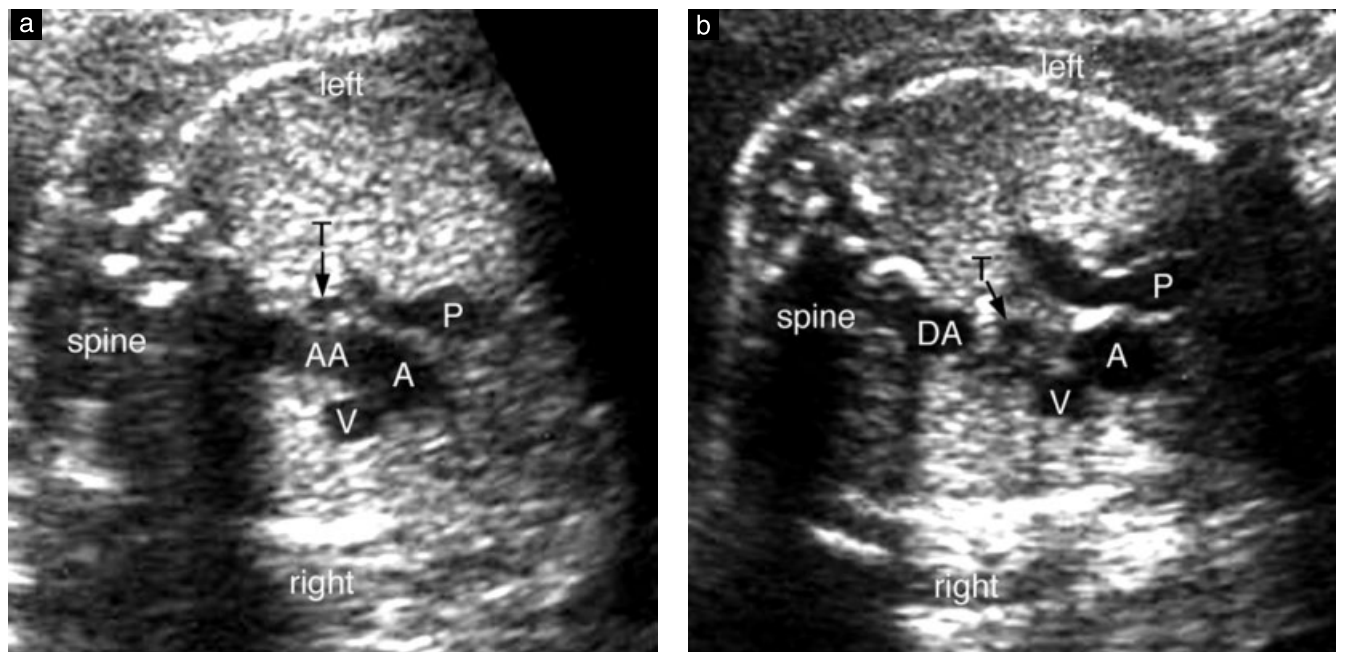


Figure 7 Right aortic arch (AA). (a) Transverse sonogram through the aortic arch shows that it is on the right side of the trachea (T). (b) Three-vessel view shows that the descending aorta (DA) is on the right side. A, ascending (ventral) aorta; P, main pulmonary artery; V, superior vena cava.

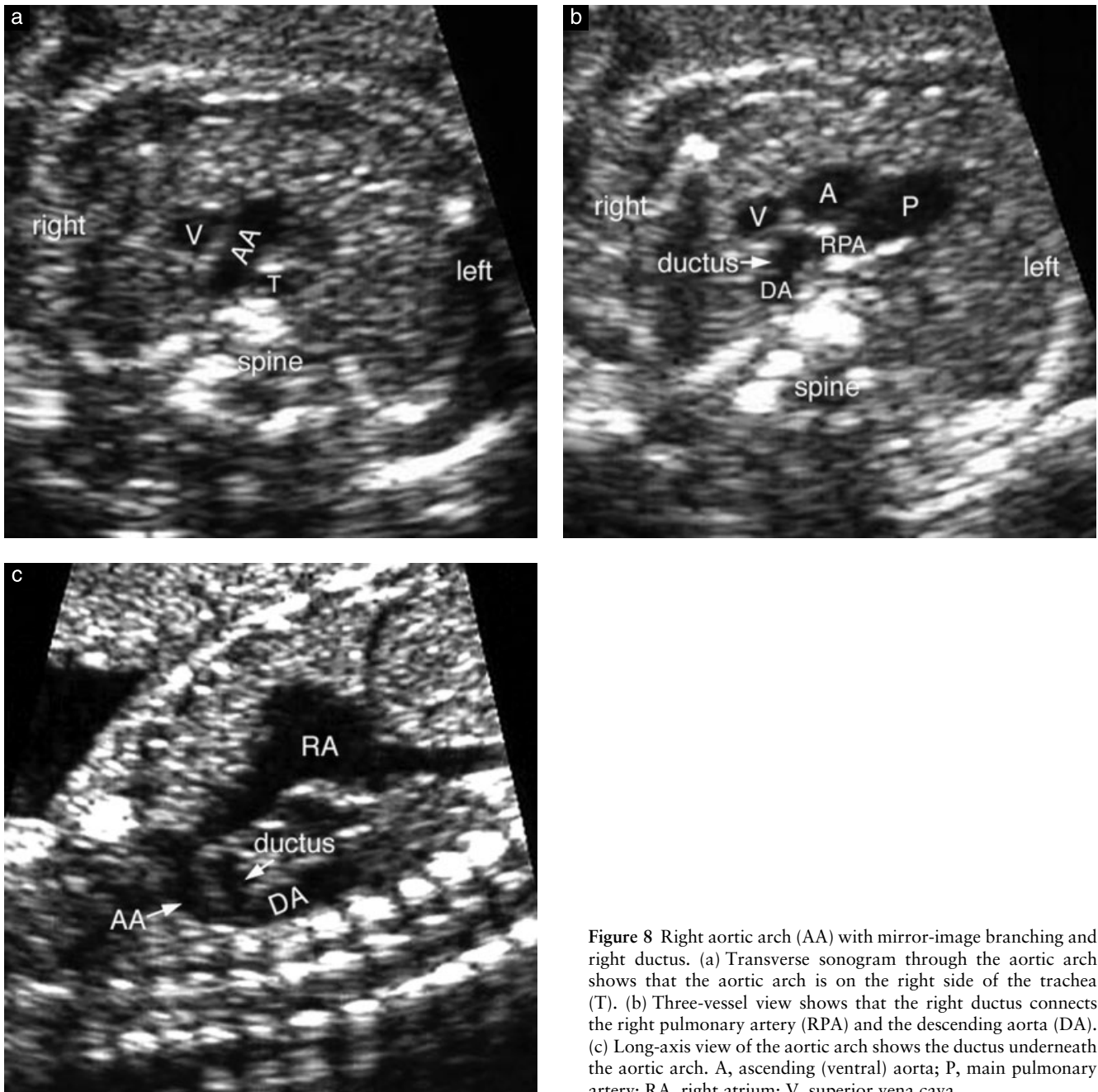


Figure 8 Right aortic arch (AA) with mirror-image branching and right ductus. (a) Transverse sonogram through the aortic arch shows that the aortic arch is on the right side of the trachea (T). (b) Three-vessel view shows that the right ductus connects the right pulmonary artery (RPA) and the descending aorta (DA). (c) Long-axis view of the aortic arch shows the ductus underneath the aortic arch. A, ascending (ventral) aorta; P, main pulmonary artery; RA, right atrium; V, superior vena cava.

the ductus and the aortic arch is not in a horizontal plane because the right ductus is located below the aortic arch to connect to the right pulmonary artery (Figure 8). When the right aortic arch is associated with tetralogy of Fallot, the patent ductus tends to be small and the blood flow through it can be reversed or bidirectional⁶. Therefore, it is often difficult to identify the ductus in this situation.

RIGHT AORTIC ARCH WITH ABERRANT LEFT SUBCLAVIAN OR INNOMINATE ARTERY

A right aortic arch can also be formed with regression of the left aortic arch segment between the origins of

the left common carotid and subclavian arteries of the double aortic arch model (Figure 9). As a consequence, the right aortic arch gives rise to the left common carotid artery as the first branch followed by the right common carotid, right subclavian and left subclavian arteries in sequence. As the left subclavian artery arises from the descending aorta and courses leftward behind the trachea and esophagus, it is called an aberrant retroesophageal left subclavian artery. Rarely, the left aortic arch is interrupted proximal to the origin of the left common carotid artery, resulting in a right aortic arch with an aberrant retroesophageal left innominate artery. The reported incidence of association with congenital heart disease varies from 10% to 50%¹⁻⁴.

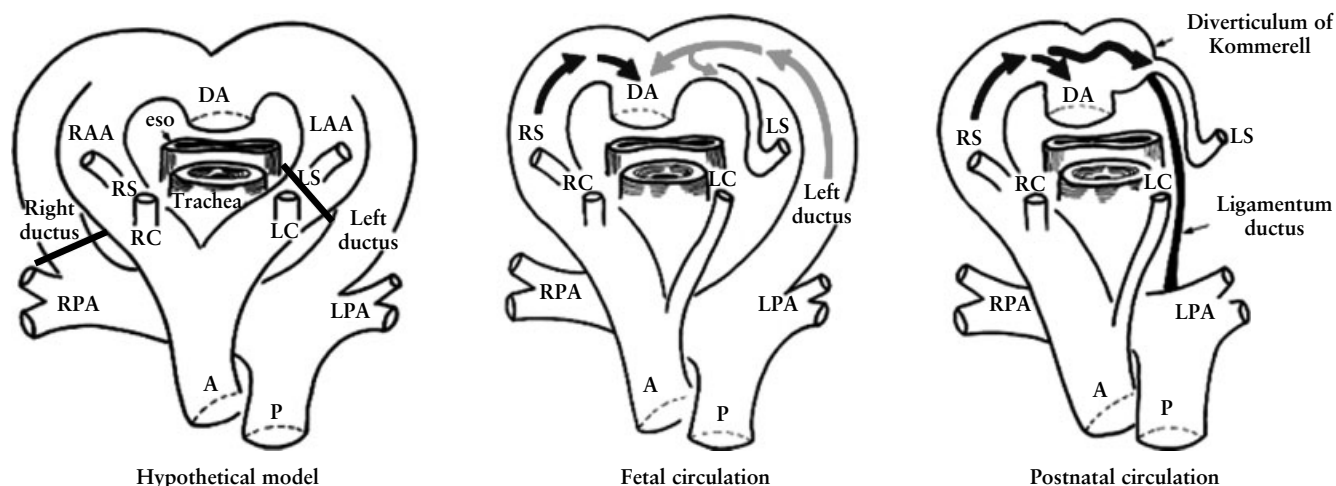


Figure 9 Developmental model of right aortic arch (AA) with aberrant left subclavian artery. The black bars in the left-hand diagram indicate the segments that regress. Usually the left ductus arteriosus persists. Fetal circulation is characterized by confluence of the blood flow through the ascending aorta (black arrow) and the blood flow through the left ductus arteriosus (gray arrow). The right aortic arch (RAA) and left ductus with a short segment of the left subclavian artery (LS) form a 'U'-shaped confluence at the descending aorta (DA). Postnatally, when the ductus closes, the proximal part of the aberrant subclavian artery persists as the diverticulum of Kommerell. Note that the blood flow in this particular segment of the left subclavian artery is in an opposite direction in fetal life. A, ascending (ventral) aorta; eso, esophagus; LAA, left aortic arch; LC, left common carotid artery; LPA, left pulmonary artery; P, main pulmonary artery; RPA, right pulmonary artery; RS, right subclavian artery.

In most cases with a right aortic arch with an aberrant left subclavian or innominate artery, the ductus persists on the left side between the aberrant artery and the left pulmonary artery (Figure 9)¹⁻⁴. In this setting, the ascending aorta, right aortic arch, aberrant left subclavian or innominate artery, left ductus and pulmonary arterial trunk, together with the heart, form a vascular ring around the trachea and esophagus. On transverse view of the aortic arch, the aortic arch, proximal part of the aberrant left subclavian artery, left-sided ductus and pulmonary artery form a 'U'-shaped vascular loop around the trachea (Figure 10)⁹. In a coronal view of the trachea and bronchi, the aortic arch is seen on the right side of the trachea, and the ductus on the left side, which is not different from the finding seen with double aortic arch (Figure 11).

In fetal life, most of the main pulmonary arterial blood flow passes into the descending aorta through the ductus. When a right aortic arch is associated with an aberrant subclavian or innominate artery and a left ductus, the proximal part of the aberrant artery carries the blood flow from the ductus into the descending aorta. Therefore, the proximal part of the aberrant artery is as wide as the ductus and descending aorta, and the blood flow through it is reversed. With closure of the ductus immediately after birth, the aberrant artery loses its blood flow from the pulmonary artery and gets blood flow from the descending aorta. The proximal part of the aberrant left subclavian or innominate artery that carried the ductal blood flow to the descending aorta remains dilated as a diverticular pouch. This dilated segment is known as the aortic diverticulum of Kommerell (Figure 12)^{1,2}.

Persistence of the right ductus is uncommon when the right aortic arch occurs with an aberrant branch. In this combination, a sling or an incomplete vascular ring is formed around the trachea and esophagus. In this setting,

the diameter of the aberrant left subclavian or innominate artery is uniform throughout^{1,2}.

LEFT AORTIC ARCH WITH ABERRANT RIGHT SUBCLAVIAN OR INNOMINATE ARTERY

This type is a mirror-image pattern of the right aortic arch with aberrant left subclavian or innominate artery that is described above. It is formed by regression of the right aortic arch segment between the origins of the right common carotid and subclavian arteries of the double aortic arch model. The consequence is the abnormal sequence of the head and neck branches; the right common carotid being the first branch followed by the left common carotid, left subclavian and aberrant retroesophageal right subclavian arteries in sequence. Rarely, the right aortic arch is interrupted proximal to the origin of the right common carotid artery, resulting in a left aortic arch with an aberrant retroesophageal right innominate artery. Association with congenital heart disease is common, especially in Down syndrome cases¹⁻⁴.

The ductus usually persists on the left side^{1,3}. Uncommonly, the right ductus persists between the aberrant right subclavian or innominate artery and the right pulmonary artery, forming a complete vascular ring. In this situation, the proximal part of the aberrant artery is a wide channel carrying the blood from the ductus into the descending aorta. After birth, with closure of the ductus, the dilated proximal part persists as the aortic diverticulum of Kommerell.

DOUBLE AORTIC ARCH

Double aortic arch represents a persistence of both right and left fourth aortic arches that form a complete vascular

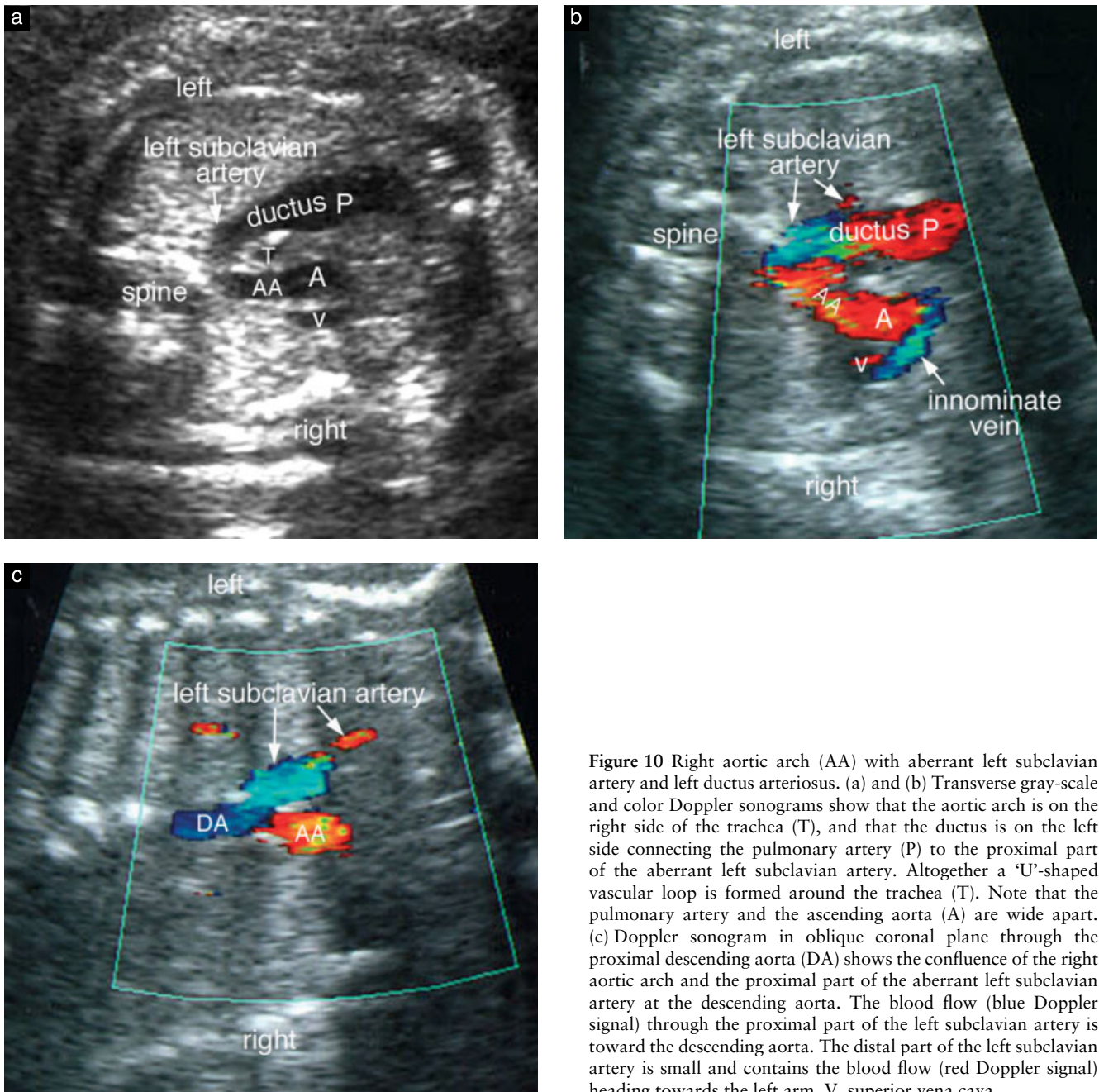


Figure 10 Right aortic arch (AA) with aberrant left subclavian artery and left ductus arteriosus. (a) and (b) Transverse gray-scale and color Doppler sonograms show that the aortic arch is on the right side of the trachea (T), and that the ductus is on the left side connecting the pulmonary artery (P) to the proximal part of the aberrant left subclavian artery. Altogether a 'U'-shaped vascular loop is formed around the trachea (T). Note that the pulmonary artery and the ascending aorta (A) are wide apart. (c) Doppler sonogram in oblique coronal plane through the proximal descending aorta (DA) shows the confluence of the right aortic arch and the proximal part of the aberrant left subclavian artery at the descending aorta. The blood flow (blue Doppler signal) through the proximal part of the left subclavian artery is toward the descending aorta. The distal part of the left subclavian artery is small and contains the blood flow (red Doppler signal) heading towards the left arm. V, superior vena cava.

ring around the trachea and esophagus (Figure 13). Although the aortic arches may be symmetrical, one arch is usually larger and higher than the other, the right arch being the larger one in approximately 75% of cases¹⁻⁴. Rarely, one arch is atretic. The common carotid and subclavian arteries arise separately from each arch and are usually symmetrically arranged. In most cases, only one ductus is patent, the left ductus being patent in the majority of cases. Almost always, the descending aorta is deviated to one side or another, usually to the side of the patent ductus. Double aortic arch is associated with congenital heart disease in approximately 20% of cases³.

On transverse view, the vascular ring of double aortic arch can be seen to encircle the fluid-filled trachea

(Figure 14). When one arch is significantly higher than the other, it is necessary to tilt the transducer to one side or another to visualize both arches. The vascular ring and ductus can be imaged in a single imaging plane, giving rise to an appearance of a figure of '6' or '9'. When one of the two arches is atretic it is almost impossible to differentiate it from a unilateral arch with an abnormal branching. In coronal view of the trachea and bronchi, cross-sections of the aortic arches are seen on both sides of the trachea (Figure 15). However, the coronal view of the double aortic arch is not distinguishable from that of right or left arch with an aberrant artery and a patent ductus on the side of the aberrant artery (Figure 11).

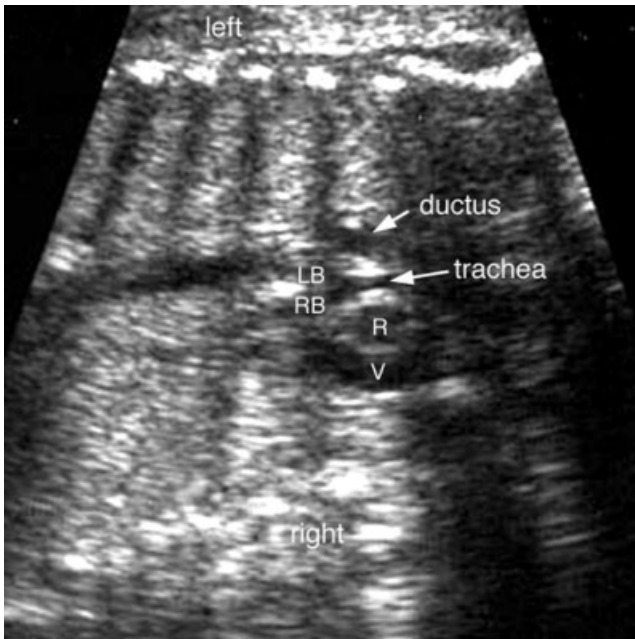


Figure 11 Right aortic arch with aberrant left subclavian artery. Coronal sonogram of the chest shows the aortic arch (R) on the right side of the trachea and the ductal arch on the left side. It is not distinguishable from the coronal view of the double aortic arch as shown in Figure 15. LB, left main bronchus; RB, right main bronchus; V, superior vena cava.

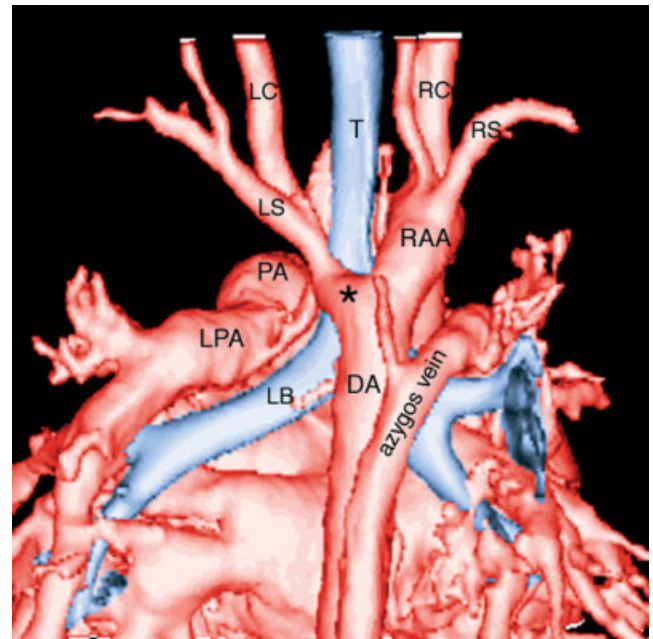


Figure 12 Right aortic arch with aberrant left subclavian artery in a 9-month-old child. Contrast-enhanced three-dimensional computed tomography image seen from behind shows the right aortic arch (RAA) and the aberrant left subclavian artery (LS) arising from the diverticulum of Kommerell (asterisk) of the descending aorta (DA). The presence of diverticulum suggests that a left ligamentum ductus connects the apex of the diverticulum and the proximal left pulmonary artery (LPA), completing a vascular ring. As an incidental finding, the right vertebral artery has a separate origin from the right aortic arch between the right common carotid (RC) and right subclavian (RS) arteries. LC, left common carotid artery; LB, left main bronchus; PA, pulmonary artery; RS, right subclavian artery; T, trachea.

CIRCUMFLEX RETROESOPHAGEAL AORTIC ARCH

Usually the aortic arch is connected to the descending aorta on the same side. When either the left or right aortic arch is connected to the descending aorta on the opposite side, the distal segment of the aortic arch crosses the midline behind the esophagus (Figure 16). This condition has been designated as circumflex retroesophageal aortic arch^{1-3,15}. The head and neck branches of the aortic arch can be normally arranged when the aortic arch is left-sided

or they can be mirror-imaged when there is a right aortic arch. An aberrant right or left subclavian artery can be present. The ductus can be on either side. When the ductus is between the descending aorta and the pulmonary artery on the other side of the aortic arch, a complete vascular

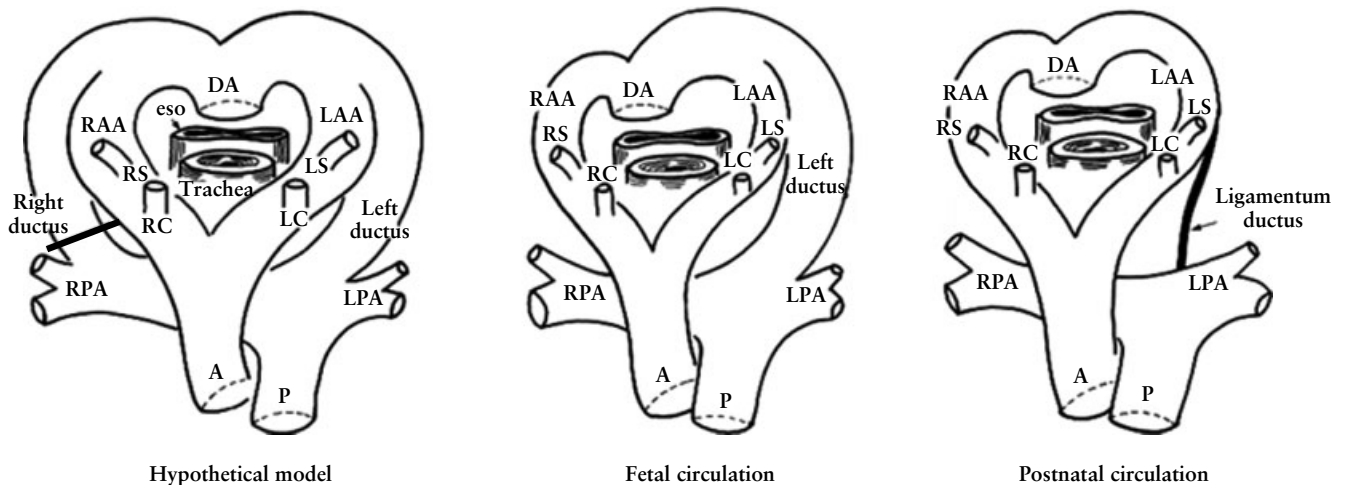


Figure 13 Developmental model of double aortic arch. The two arches encircle the trachea and esophagus. A, ascending (ventral) aorta; DA, descending (dorsal) aorta; eso, esophagus; LAA, left aortic arch; LC, left common carotid artery; LPA, left pulmonary artery; LS, left subclavian artery; P, main pulmonary artery; RAA, right aortic arch, RC, right common carotid artery; RPA, right pulmonary artery; RS, right subclavian artery.

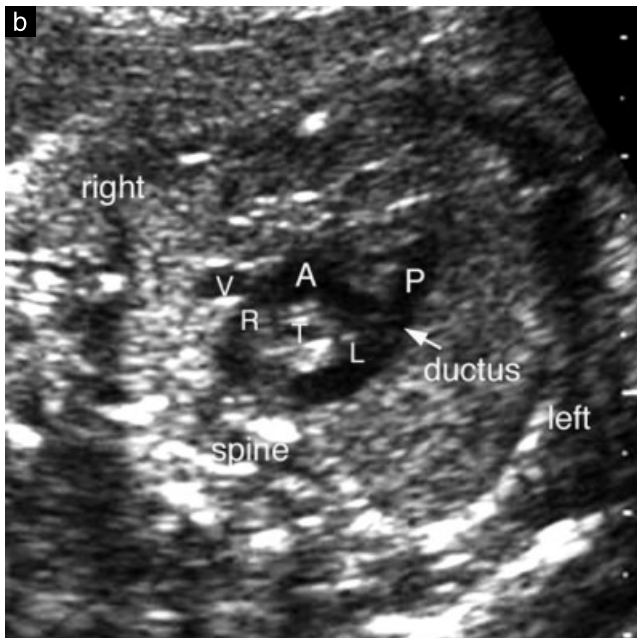
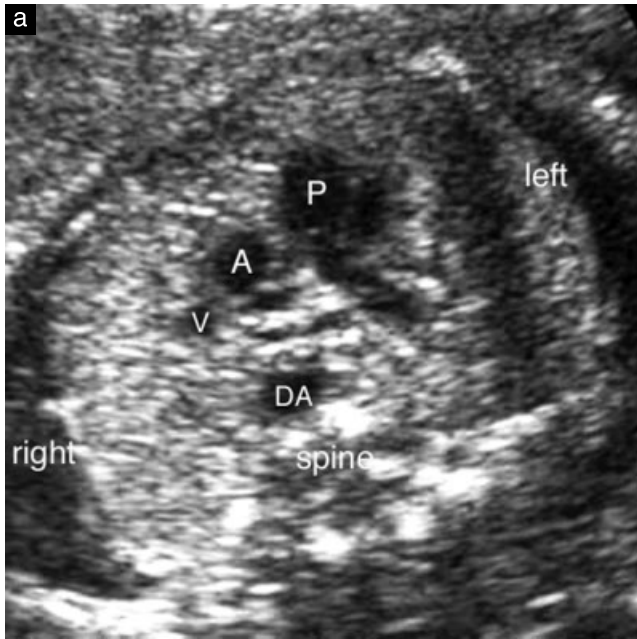


Figure 14 Double aortic arch with left-sided ductus. (a) Three-vessel view shows the descending aorta (DA) slightly displaced to the right. (b) Transverse sonogram of the aortic arch shows that the two aortic arches (R and L) completely encircle the trachea (T). The left ductus arteriosus connects the pulmonary artery (P) to the left aortic arch. The aortic arches, ductus and pulmonary artery together form a figure of '9'. A, ascending (ventral) aorta; V, superior vena cava.

Figure 16 Circumflex retroesophageal aortic arch. The aortic arch connects to the descending aorta (DA) on the other side forming a vascular sling around the trachea and esophagus. Its pathogenetic mechanism is hard to explain. The ductus can be present on either side. A, ascending (ventral) aorta; DA, descending (dorsal) aorta; eso, esophagus; LAA, left aortic arch; LC, left common carotid artery; LPA, left pulmonary artery; LS, left subclavian artery; P, main pulmonary artery; RAA, right aortic arch, RC, right common carotid artery; RI, right innominate artery; RPA, right pulmonary artery; RS, right subclavian artery.

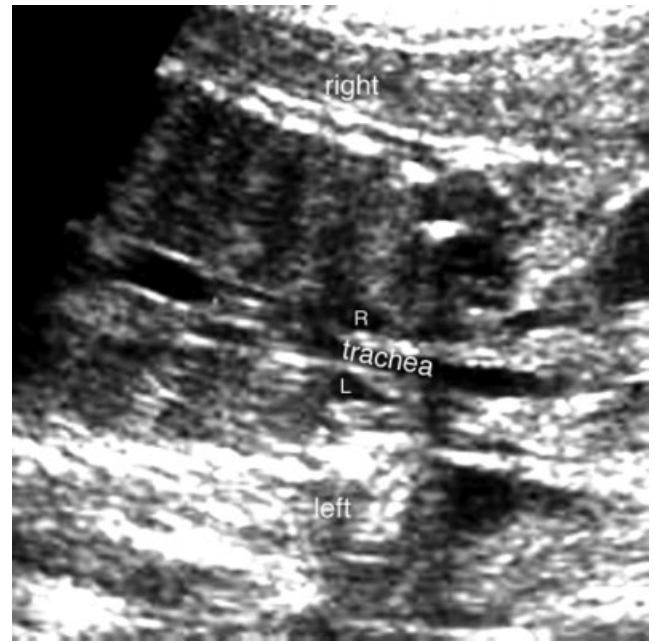
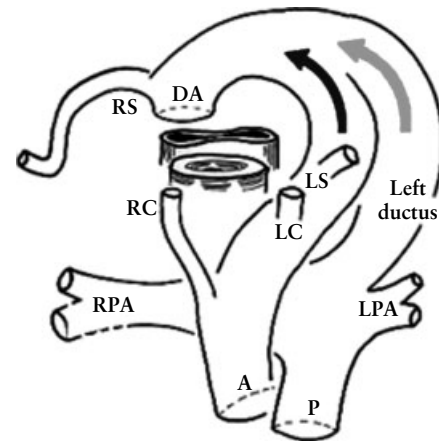
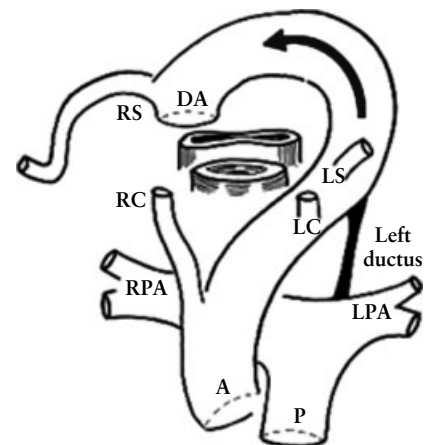


Figure 15 Double aortic arch. Coronal sonogram of the chest shows two aortic arches (R and L), one on each side of the trachea.



Fetal circulation



Postnatal circulation

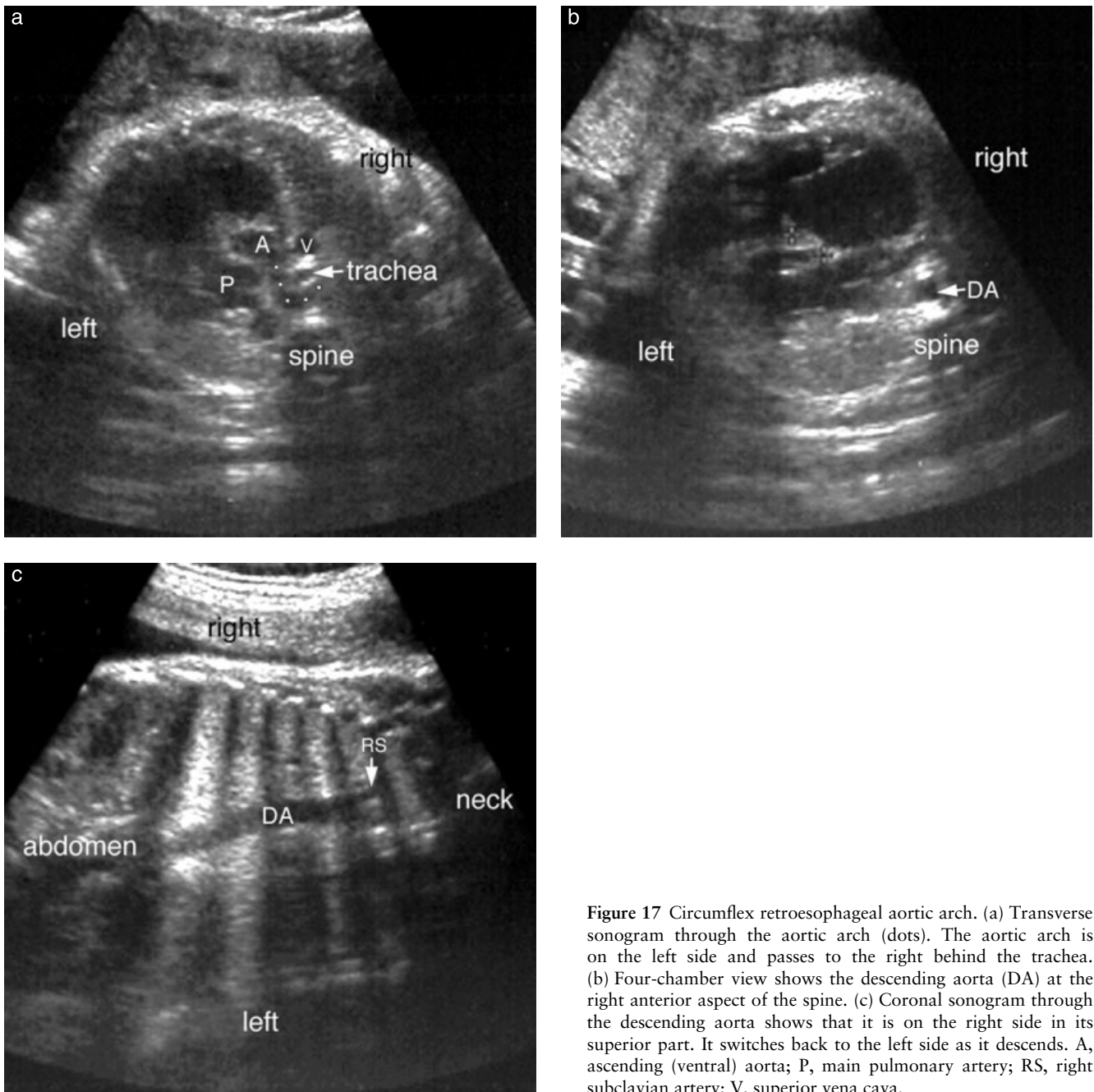


Figure 17 Circumflex retroesophageal aortic arch. (a) Transverse sonogram through the aortic arch (dots). The aortic arch is on the left side and passes to the right behind the trachea. (b) Four-chamber view shows the descending aorta (DA) at the right anterior aspect of the spine. (c) Coronal sonogram through the descending aorta shows that it is on the right side in its superior part. It switches back to the left side as it descends. A, ascending (ventral) aorta; P, main pulmonary artery; RS, right subclavian artery; V, superior vena cava.

ring is formed. Association with congenital heart disease is not uncommon. The retroesophageal component of the aortic arch often produces significant compression of the esophagus and airway. Its pathogenetic mechanism is unclear.

Both during fetal sonography and postnatal imaging, a circumflex retroesophageal aortic arch is indistinguishable from a double aortic arch with an atretic segment. Differentiation between the two can only be achieved by surgical or pathological exploration. On a transverse sonogram, the aortic arch forms a sling on either side of the trachea to connect to the descending aorta on the opposite side (Figure 17). Commonly, circumflex

retroesophageal arch extends to the level of the thoracic inlet forming a cervical arch.

SUMMARY

Insight into the hypothetical arch model is crucial to understanding anomalies of the aortic arch in the fetus. Axial views of the upper fetal mediastinum and recognition of the trachea, three major vessels, ductus and descending aorta are necessary steps of a complete fetal cardiac assessment. Clues to arch anomalies include abnormal position of the descending aorta, absence of the normal 'V'-shaped confluence of the ductal and

aortic arches, a gap between the ascending aorta and main pulmonary artery in the three-vessel view, and an abnormal vessel behind the trachea with or without a 'U', 'l', '6' or '9'-shaped vascular loop or ring around the trachea. Meticulous attention to anatomic landmarks will lead to successful prenatal diagnosis of important vascular rings making early postnatal management possible.

REFERENCES

1. Moes CAF. Vascular rings and related conditions. In *Congenital Heart Disease*, Freedom RM, Mawson JB, Yoo SJ, Benson LN (eds). *Textbook of Angiocardiograph*. Armonk, NY: Futura Publishing Co., 1997; 947–983.
2. Weinberg PM. Aortic arch anomalies. In *Heart Disease in Infants, Children, and Adolescents*, Emmanouilides GC, Allen HD, Riemenschneider TA, Gutgesell HP (eds). Baltimore, MD: Williams & Wilkins: 1995; 810–837.
3. Park SC, Zuberbuhler JR. Vascular ring and pulmonary sling. In *Pediatric Cardiology*, Anderson RH, Macartney FJ, Shinebourne EA, Tynan M (eds). Edinburgh, UK: Churchill Livingstone: 1987; 1123–1136.
4. Edwards JE. Vascular rings and slings. In *Fetal, Neonatal, and Infant Cardiac Disease*, Moller JH, Neal WA (eds). Norwalk, CT: Appleton & Lange: 1990; 745–754.
5. Bronshtein M, Lorber A, Berant M, Auslander R, Zimmer EZ. Sonographic diagnosis of fetal vascular rings in early pregnancy. *Am J Cardiol* 1998; **81**: 101–103.
6. Yoo SJ, Lee YH, Kim ES, Ryu HM, Kim MY, Yang JH, Chun YK, Hong SR. Tetralogy of Fallot in the fetus: findings at targeted sonography. *Ultrasound Obstet Gynecol* 1999; **14**: 29–37.
7. Yoo SJ, Lee YH, Cho KS, Kim DY. Sequential segmental approach to fetal congenital heart disease. *Cardiol Young* 1999; **9**: 430–444.
8. Hornberger LK. Aortic arch anomalies. In *Textbook of Fetal Cardiology*, Allan L, Hornberger L, Sharland G (eds). London, UK: Greenwich Medical Media: 2000; 305–321.
9. Achiron R, Rotstein Z, Heggesh J, Bronshtein M, Zimand S, Lipitz S, Yagel S. Anomalies of the fetal aortic arch: a novel sonographic approach to *in utero* diagnosis. *Ultrasound Obstet Gynecol* 2002; **20**: 553–557.
10. Edwards JE. "Vascular rings" related to anomalies of the aortic arches. *Mod Concepts Cardiovasc Dis* 1948; **17**: 19–20.
11. Edwards JE. Malformation of the aortic arch system manifested as "vascular rings". *Lab Invest* 1953; **2**: 56–75.
12. Yoo SJ, Lee YH, Kim ES, Ryu HM, Kim MY, Choi HK, Cho KS, Kim A. Three-vessel view of the fetal upper mediastinum; an easy means of detecting abnormalities of the ventricular outflow tracts and great arteries during obstetric screening. *Ultrasound Obstet Gynecol* 1997; **9**: 173–182.
13. Yagel S, Arbel R, Anteby EY, Raveh D, Achiron R. The three vessels and trachea view (3VT) in fetal cardiac scanning. *Ultrasound Obstet Gynecol* 2002; **20**: 340–345.
14. Chaoui R, McEwing R. Three cross-sectional planes for fetal color Doppler echocardiography. *Ultrasound Obstet Gynecol* 2003; **21**: 81–93.
15. Hastreiter AR, D'Cruz IA, Cantez T, Namin EP, Licata R. Right-sided aorta. I. Occurrence of right aortic arch in various types of congenital heart disease. II. Right aortic arch, right descending aorta, and associated anomalies. *Br Heart J* 1966; **28**: 722–739.