



# ISUOG

## Virtual World Congress

### on Ultrasound in Obstetrics and Gynecology

Share your research with our large international ultrasound community including leading names in the field. Submit your abstract for the chance to present orally or via an electronic poster presentation at our Virtual World Congress this October.



### Key dates for submission

- 15 June 2021: Abstract submission deadline
- July 2021: Notification of acceptance or rejection
- 16 August 2021: Presenting authors registration deadline

**Submit your abstract now**





## ESGO/ISUOG/IOTA/ESGE Consensus Statement on preoperative diagnosis of ovarian tumors

### ABSTRACT

The European Society of Gynaecological Oncology (ESGO), the International Society of Ultrasound in Obstetrics and Gynecology (ISUOG), the International Ovarian Tumour Analysis (IOTA) group and the European Society for Gynaecological Endoscopy (ESGE) jointly developed clinically relevant and evidence-based statements on the preoperative diagnosis of ovarian tumors, including imaging techniques, biomarkers and prediction models.

ESGO/ISUOG/IOTA/ESGE nominated a multidisciplinary international group, including expert practising clinicians and researchers who have demonstrated leadership and expertise in the preoperative diagnosis of ovarian tumors and management of patients with ovarian cancer (19 experts across Europe). A patient representative was also included in the group. To ensure that the statements were evidence-based, the current literature was reviewed and critically appraised.

Preliminary statements were drafted based on the review of the relevant literature. During a conference call, the whole group discussed each preliminary statement and a first round of voting was carried out. Statements were removed when consensus among group members was not obtained. The voters had the opportunity to provide comments/suggestions with their votes. The statements were then revised accordingly. Another round of voting was carried out according to the same rules to allow the whole group to evaluate the revised version of the statements. The group achieved consensus on 18 statements.

This Consensus Statement presents these ESGO/ISUOG/IOTA/ESGE statements on the preoperative diagnosis of ovarian tumors and the assessment of carcinomatosis, together with a summary of the evidence supporting each statement.

### INTRODUCTION

The accurate characterization of newly diagnosed adnexal lesions is of paramount importance to define appropriate treatment pathways. Patients with masses that are suspicious for malignancy should be referred to a gynecological oncology center, in order to receive specialist care, as per the definitions of the European Society of Gynaecological Oncology (ESGO)<sup>1</sup> and national and international recommendations and guidelines. For a non-gynecological primary tumor, patients need to be referred to an appropriate specialist, while patients with benign lesions may be followed up and treated conservatively or may be suitable for less radical surgical treatment, depending on the clinical context<sup>2-7</sup>. Treatment decision-making processes should be based on a combination of the patient's overall clinical picture, symptoms, preferences, previous medical and surgical history, tumor markers and clinical and radiological findings. A single diagnostic modality alone should not determine the patient's journey.

The ESGO, the International Society of Ultrasound in Obstetrics and Gynecology (ISUOG), the International Ovarian Tumour Analysis (IOTA) group and the European Society for Gynaecological Endoscopy (ESGE) have, jointly, developed clinically relevant and evidence-based statements on the preoperative diagnosis of ovarian tumors and assessment of disease spread, including imaging techniques, biomarkers and predictive models. Neither screening and follow-up modalities, nor economic analysis of the imaging techniques, biomarkers and prediction models addressed herein, are included within the remit of this Consensus Statement.

### RESPONSIBILITIES

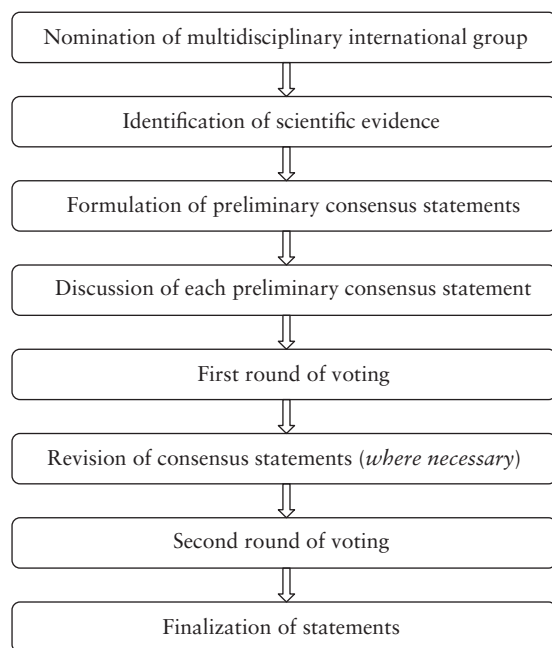
The present series of statements form a consensus of the authors regarding their currently accepted

This paper is being published simultaneously and jointly, in *International Journal of Gynecological Cancer, Ultrasound in Obstetrics & Gynecology* and *Facts, Views and Vision in ObGyn* © 2021, by the European Society of Gynecological Oncology (ESGO), the International Society of Ultrasound in Obstetrics and Gynecology (ISUOG), the International Ovarian Tumour Analysis (IOTA) group and the European Society for Gynaecological Endoscopy (ESGE). All rights reserved.

approaches for the preoperative diagnosis of ovarian tumors and assessment of disease spread, based on the available literature and evidence. Any clinician applying or consulting these statements is expected to use independent medical judgment in the context of individual clinical circumstances to determine all patients' care and treatment. These statements are presented without any warranty regarding their content, use or application and the authors disclaim any responsibility for their application or use in any way.

## METHODS

This Consensus Statement on the preoperative diagnosis of ovarian tumors and assessment of disease spread was developed using an eight-step process, chaired by Professors Christina Fotopoulou and Dirk Timmerman (Figure 1). Aiming to assemble a multidisciplinary international group, ESGO/ISUOG/IOTA/ESGE nominated 19 practising clinicians and researchers who have demonstrated leadership and expertise in the preoperative diagnosis of ovarian tumors and clinical management of ovarian cancer patients through research, administrative responsibilities, and/or committee membership (including eight members of ESGO, five members of ISUOG, four members of IOTA and two members of ESGE). These experts included seven gynecologists with special interest in ultrasonography, two radiologists and 10 gynecological oncologists. They did not represent the societies from which they were selected, and were asked to base their decisions on their own experience and expertise. Also included in the group was a patient representative, who is Chair of the Clinical Trial Project of the



**Figure 1** Eight-step process for development of Consensus Statement on the preoperative diagnosis of ovarian tumors and assessment of disease spread.

European Network of Gynaecological Cancer Advocacy Groups, ENGAGE. An initial conference call, including the whole group, was held to facilitate introductions, as well as to review the purpose and scope of this Consensus Statement.

To ensure that the statements were evidence-based, the current literature was reviewed and critically appraised. Thus, a systematic literature review of relevant studies published between 1 May 2015 and 1 May 2020 was carried out using the MEDLINE database (Appendix 1). The literature search was limited to publications in the English language. Priority was given to high-quality systematic reviews, meta-analyses and validating cohort studies, although studies with lower levels of evidence were also evaluated. The search strategy excluded editorials, letters and case reports. The reference list of each identified article was reviewed for other potentially relevant articles. Final results of the literature search were distributed to the whole group, including electronic full-text versions of each article. F. Planchamp provided the methodology and medical writing support for the entire process, and did not participate in voting for statements.

The chairs were responsible for drafting preliminary statements based on the review of the relevant literature. These were then sent to the multidisciplinary international group prior to a second conference call. During this conference call, the whole group discussed each preliminary statement and a first round of binary voting (agree/disagree) was carried out for each potential statement. All 20 participants took part in each vote, but they were permitted to abstain from voting if they felt they had insufficient expertise to agree/disagree with the statement or if they had a conflict of interest that could be considered to influence their vote. Statements were removed when a consensus among group members was not obtained. The voters had the opportunity to provide comments/suggestions with their votes. The chairs then discussed the results of this first round of voting and revised the statements if necessary. The voting results and the revised version of the statements were again sent to the whole group and another round of binary voting was organized, according to the same rules, to allow the whole group to evaluate the revised version of the statements. The statements were finalized based on the results of this second round of voting. The group achieved consensus on 18 statements. In this Consensus Statement, we present a summary of the supporting evidence, the finalised series of statements, and their levels of evidence and grades.

## RESULTS

### General remarks

Even though the test performance of any biochemical or radiological diagnostic test appears to increase after excluding borderline ovarian tumors and non-gynecological primary tumors, such as of the gastrointestinal tract or breast, we included in our literature

assessment studies addressing all types of adnexal tumor, as this is a better reflection of clinical reality.

### Ultrasonography

A transvaginal ultrasound examination is often regarded in clinical practice as the standard first-line imaging investigation for the assessment of adnexal pathology<sup>8–11</sup>. The diagnostic accuracy of ultrasonography in differentiating between benign and malignant adnexal masses has been shown to relate to the expertise of the operator<sup>12–14</sup>. The European Federation of Societies for Ultrasound in Medicine and Biology has published minimum training requirements for gynecological ultrasound practice in Europe, including standards for theoretical knowledge and practical skills<sup>15</sup>. These identify three levels of training and expertise. Thus, Level III (expert) can be attributed to a practitioner who is likely to spend the majority of their time undertaking gynecological ultrasound and/or teaching, research and development in the field. A Level-II practitioner should have undertaken at least 2000 gynecological ultrasound examinations. The training required to attain this level of practice would usually be gained during a period of expert ultrasound training, which may be within, or after completion of, a specialist training program. To maintain competence at Level II, practitioners should perform at least 500 examinations each year. A Level-I practitioner should have performed a minimum of 300 examinations under the supervision of a Level-II practitioner or an experienced Level-I practitioner with at least 2 years' regular practical experience. To maintain Level-I status, the practitioner should perform at least 300 examinations each year. A prospective randomized controlled trial to assess the effect of the quality of gynecological ultrasonography on the management of patients with suspected ovarian cancer has demonstrated that women with a Level-III (expert) ultrasound examination undergo significantly fewer unnecessary major procedures and have a shorter inpatient hospital stay compared with those having a Level-II (routine) examination by a sonographer<sup>14</sup>.

Subjective assessment by expert ultrasound examiners has excellent performance to distinguish between benign and malignant ovarian tumors<sup>9–14</sup>. In many cases, expert examiners should be able to narrow the diagnosis down further, to a specific histological subtype. The typical pathognomonic ultrasound features of some key histological types have been published in the series, 'Imaging in gynecological disease', in *Ultrasound in Obstetrics and Gynecology* ([https://obgyn.onlinelibrary.wiley.com/doi/toc/10.1002/\(ISSN\)1469-0705.IMAGINGYNECOLOGICALDISEASE](https://obgyn.onlinelibrary.wiley.com/doi/toc/10.1002/(ISSN)1469-0705.IMAGINGYNECOLOGICALDISEASE)). The most common and typical findings for each pathology are summarized in Table 1.

### *Risk of malignancy index (RMI) and risk of ovarian malignancy algorithm (ROMA)*

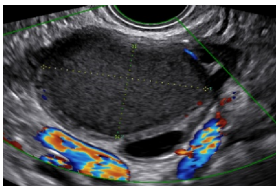
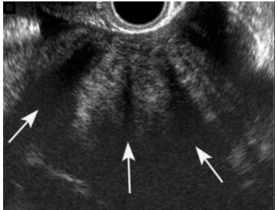

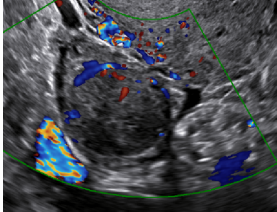
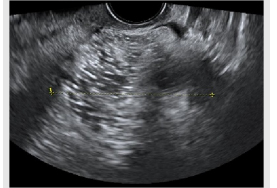

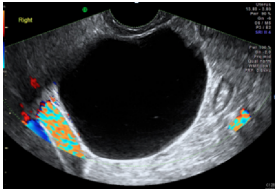
Several attempts have been made to develop more objective ultrasound-based approaches for discriminating

between benign and malignant adnexal tumors. These include the risk of malignancy index (RMI), a scoring system based on menopausal status, a transvaginal ultrasound score and serum cancer antigen 125 (CA 125) level<sup>16</sup>. Many studies have demonstrated the diagnostic performance of the RMI in classifying adnexal masses<sup>11,17–29</sup>. Three variants of the RMI (RMI-II, RMI-III, RMI-IV) have been developed, but these offer no significant additional diagnostic advantage compared with the original version (RMI-I)<sup>11,22,27,28</sup>. Moore *et al.*<sup>30</sup> developed an algorithm, the risk of ovarian malignancy algorithm (ROMA), based on both CA 125 and human epididymis protein 4 (HE4). Westwood *et al.*<sup>18</sup> pooled data comparing the ROMA with the RMI-I to guide referral decisions for women with suspected ovarian cancer and found similar performance if women with borderline tumors and non-epithelial cancers were excluded from the analyses. More recently, another meta-analysis showed a higher specificity of the RMI-I than the ROMA in premenopausal women but a similar performance for detecting ovarian cancer in postmenopausal women presenting with an adnexal mass<sup>17</sup>. Limitations of the RMI are the absence of an estimated risk of malignancy, and its considerable dependence on serum CA 125, the latter resulting in a relatively low sensitivity for early-stage invasive and borderline disease, especially in premenopausal women<sup>31,32</sup> (see Tumor markers).

### *IOTA methods*

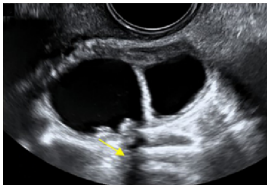
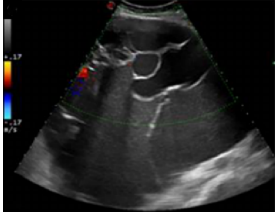
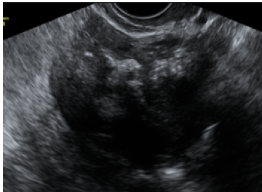
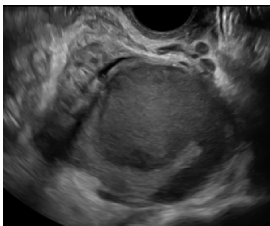
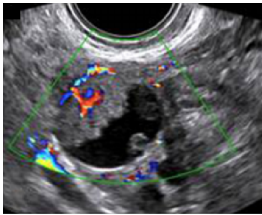
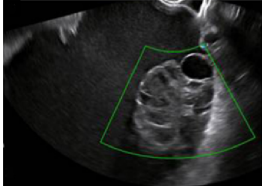
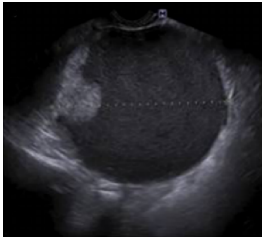
To homogenize and standardize the quality, description and evaluation of ultrasonography across different centers, and thereby increase diagnostic accuracy, the IOTA group first published a consensus paper on terms and definitions to describe adnexal lesions in 2000<sup>33</sup>. Using this standardized methodology, the IOTA group has developed different prediction models based on logistic regression analysis<sup>34–36</sup>. In a large-scale external validation study, Van Holsbeke *et al.*<sup>37</sup> showed that the IOTA logistic regression models 1 (LR1, with 12 variables) and 2 (LR2, with six variables) outperformed 12 other models, including the RMI. The LR2 model was easier to use than the LR1 model. Demonstrating the standardization and reproducibility of the IOTA models, Sayasneh *et al.*<sup>38</sup> showed that even less-experienced sonographers are able to differentiate accurately between benign and malignant ovarian masses using the IOTA LR1 model. The IOTA group also developed 'Simple Rules' that may be applied to a mass based on the presence or absence of five benign and five malignant ultrasound features. These rules can be applied to about 80% of adnexal masses, with the rest being classed as inconclusive. They have now been broadly accepted and are widely used in clinical practice<sup>38–46</sup>. More recently, a logistic regression model based on the ultrasound features of the original Simple Rules was developed, i.e. the Simple Rules risk model. This model is able to provide an individual estimated risk of malignancy for any type of lesion<sup>35</sup>. A summary of the main models and scoring systems for the

**Table 1** Clinical and ultrasound features typical of different histological subtypes of adnexal tumor

Category/Type	Age (years)	Laterality	Appearance	Typical features	Color score	Image	Ref
<b>Endometriosis-related tumors</b>							
Endometrioma	Median, 34	Uni/bi	Uni- or multilocular (1–4 locules)	Ground-glass content; papillations in 10%, but most often without internal blood flow; premenopausal patient; raised CA 125 (median, 44 U/mL)	1/2/(3)		171
<b>Benign tumors</b>							
<b>Sex cord-stromal tumor</b>							
Fibroma/fibrothecoma (65%)	Median, 50; 65% postmenopausal	Uni	Regular round, oval or slightly lobulated solid tumors; sometimes multilocular-solid (15–20%)	Fan-shaped shadowing; often, raised CA 125 (34%) and/or ascites	(1)/2/3		172
Sertoli-cell tumor (most benign)	≤ 30 (75%)	Uni	Solid; median diameter, 90 mm	Hormonally inactive or estrogen-producing (abnormal bleeding)	3/4		173
Leydig-cell tumor (almost all benign)	Median, 58	Uni	Solid; median diameter, 24 mm	Endocrine symptoms (75% virilization); testosterone/androstenedione	3/4		173
<b>Germ-cell tumor</b>							
Mature cystic teratoma (dermoid)	Median, 33	Uni (88%)	Uni- (58%) or multilocular (or uni-/multilocular-solid)	Mixed echogenicity/white ball and stripes/shadowing; CA 19-9 elevated in 30%	1/2/(3)		†
Struma ovarii (entirely or predominantly thyroid tissue); 3% of all ovarian teratomas	Median, 40	Uni/bi	Multilocular/multilocular-solid; rarely, papillations; fluid anechoic or low-level	'Struma pearl': smooth; roundish solid area; thyrotoxicosis may occur	1/2/3		174
<b>Epithelial</b>							
Serous cystadenoma	40–60	Uni (80–90%)	Uni- or multilocular (2–10 locules)	Anechoic cystic fluid; often, papillations without internal blood flow	1/2		‡

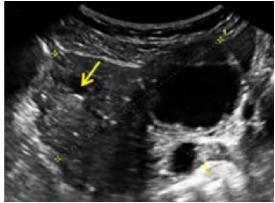



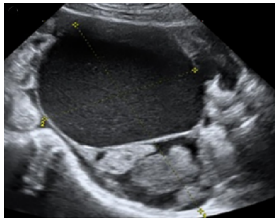
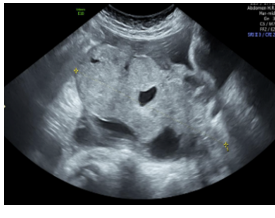
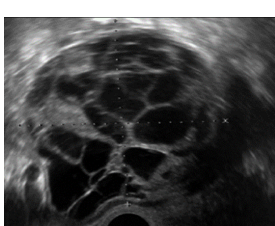
Continued over.

Table 1 Continued

Category/Type	Age (years)	Laterality	Appearance	Typical features	Color score	Image	Ref
Serous cystadenofibroma	40–60	Uni (84%)	Multilocular-solid (37%), unilocular-solid (30%), multilocular (19%) or unilocular (13%); median diameter, 50–80 mm	One (52%), two (17%) or three (13%) papillations; absent color Doppler signals (80%) and shadows behind papillations (40%)	1/2		175
Mucinous cystadenoma	Median, 50	Uni (95%)	Multilocular (65%) > 10 locules; sometimes unilocular (18%) or multilocular-solid (16%); median diameter, 112 mm	Sometimes 'honeycomb nodule'	1/2/(3)		176
Brenner tumor (99% benign)	30–70	Uni	Small solid tumors, 20–80 mm; often extensive calcifications; sometimes multilocular-solid	Small cysts often seen in solid tumors; shadowing; CA 125 raised in 10%	1/2/(3)		177
<i>Tumor-like lesions</i>							
<i>Infection</i>							
Abscess	16–50	Uni/bi	Uni-/multilocular	Cogwheel appearance; mixed echogenicity; acute pain; raised CA 125	3/4		178
<i>Malignant tumors</i>							
<i>Epithelial</i>							
Borderline serous	Median, 42; 30% < 40	Uni (73%)/bi (27%)	Unilocular-solid (55%) or multilocular-solid (30%); cystic fluid anechoic (47%) or low-level	> 3 irregular papillations (81%) with internal blood flow and anechoic spaces; no shadowing	2/3		179, 180, 181
Borderline mucinous (intestinal type) (30–50%)	Median, 50	Uni	Multilocular (80%) or unilocular (15%); very large tumor (median diameter, 195 mm)	Multiple small loculi, often 'honeycomb nodule'; no papillations; cystic fluid low-level	2/3		176, 179
Borderline mucinous (endocervical type)	30–40	Uni	Unilocular-solid; sometimes multilocular-solid; median diameter, 37 mm	Papillations (60%); cystic fluid low-level or ground-glass	2/3		176, 179


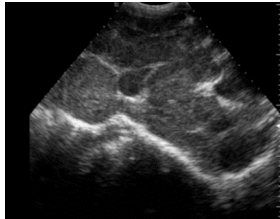
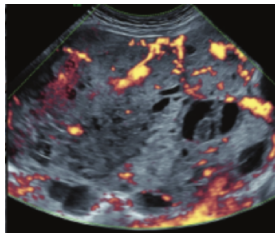
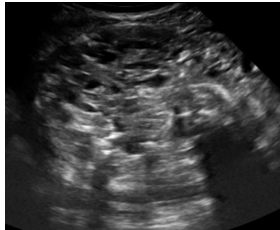
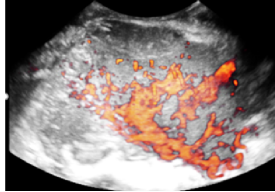
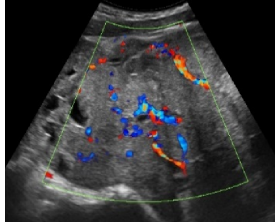
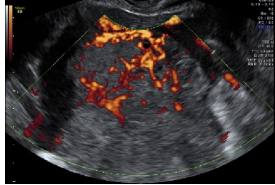
Continued over.

Table 1 Continued

Category/Type	Age (years)	Laterality	Appearance	Typical features	Color score	Image	Ref
Borderline seromucinous (new category <sup>182</sup> )	Median, 42	Uni	Contain endometrioid-, indifferent- and squamous-type epithelium	Frequently associated with endometriosis	—	—	176, 179
Low-grade serous carcinoma	Median, 53	Bi (60%)	Multilocular-solid (55%) or solid (32%)	Small calcifications in solid tissue; papillations (32%)	2/3/4		180
High-grade serous carcinoma	55–65	Bi (50%)	Solid (64%) or multilocular-solid (33%)	Areas of necrosis in solid tissue; rarely, papillations (7%)	2/3/4		180
Mucinous carcinoma (3%)	Median, 53	Uni (80%)	Multilocular-solid (55%), multilocular or solid	Very large tumor (median diameter, 197 mm); cystic fluid low-level	2/3/(4)		176
Endometrioid carcinoma (10–15%)	Median, 55	Uni (79%); coexist with endometrial carcinoma (20%)	Multilocular-solid (48%) with low-level (53%) or ground-glass (16%) cystic fluid, or solid (34%); median diameter, 102 mm	Cockade-like appearance; papillations in 29%; 20% develop from endometriosis	(2)/3/4		183
Clear-cell carcinoma (5–25%)	Median, 55	Uni (85%)	Multilocular-solid (41%), or unilocular-solid (35%) with low-level (44%) or ground-glass (22%) cystic fluid, or solid (24%); median diameter, 117 mm	Solid nodules; papillations in 38%; 20–30% develop from endometriosis	(2)/3/4		184
Carcinosarcoma	Median, 66 (range, 33–91)	Bi (50%)	Solid (72.5%); multilocular-solid (24.5%); median diameter, 100 mm	Most tumors solid with irregular margins and cystic areas	3/4		§
Sex cord-stromal tumor							
Granulosa-cell tumor (70%)	50% premenopausal; 3–10% prepubertal (juvenile type)	Uni	Large multilocular-solid/solid; median diameter, 100 mm; heterogeneous solid tissue with areas of necrosis and hemorrhage; echogenicity of fluid mixed or low-level; rarely, papillations	'Swiss cheese' pattern; hyperestrogenic (abnormal bleeding, thick endometrium); CA 125 normal; estradiol elevated in postmenopause	3/4		185

Continued over.

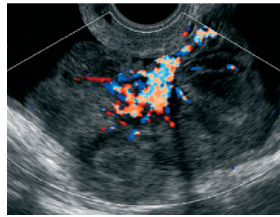
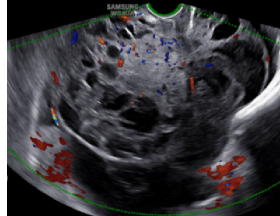
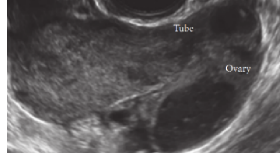
Table 1 Continued

Category/Type	Age (years)	Laterality	Appearance	Typical features	Color score	Image	Ref
Sertoli-Leydig-cell tumor	≤ 30 (75%)	Uni (100%)	Large multilocular-solid or solid; median diameter, 50–150 mm	Endocrine symptoms (one third virilization); testosterone/androstenedione	3/4		173
Germ-cell tumor Dysgerminoma	Median, 20 (range, 16–31)	Uni	Highly vascularized, purely solid tumors with heterogeneous internal echogenicity divided into several lobules; smooth and sometimes lobulated contour; well-defined relative to surrounding organs	Internal lobular appearance; raised LDH, sometimes AFP	3/4		186
Yolk-sac tumor*	20–30	Uni	Large and irregular multilocular-solid/solid (100–200 mm)	Fine-textured slightly hyperechoic solid tissue; raised AFP	3/4		187, 188
Immature teratoma	15–30	Uni	Large, predominantly solid	Very inhomogeneous solid tissue with hyper-reflective areas; raised AFP	2/3/4		¶
Choriocarcinoma	Median, 36	Uni	Large, solid (inhomogeneous echogenicity) with small and irregular cystic spaces	Raised hCG	(3)/4		189
Embryonal carcinoma	14–20	Uni	Large, solid (inhomogeneous echogenicity) with small and irregular cystic spaces	Raised hCG and AFP	(3)/4		189
Malignant mixed germ-cell tumor	Median, 18	Uni	Large, solid (inhomogeneous echogenicity) with small and irregular cystic spaces	Raised hCG/LDH/AFP	(3)/4		189

Continued over.



Table 1 Continued

Category/Type	Age (years)	Laterality	Appearance	Typical features	Color score	Image	Ref
Secondary metastatic Breast, stomach, lymphoma or uterus	Median, 56	Bi (50–75%)/uni	Solid; median diameter, 70 mm	'Lead-vessel' sign; CA 125 moderately raised in 75%; CA 15-3 raised (breast)	3/4		190
Colon, rectum, appendix or biliary tract	Median, 56; appendix younger (25–50)	Bi (50–75%)/uni	Multilocular/ multilocular- solid; median diameter, 120 mm; many locules; irregular; papillations	CA 125 moderately raised in 75%; CEA raised (colon, rectum); CA19-9 raised (biliary tract)	(2)/3(4)		190
Tumor of Fallopian tube: epithelial Tubal cancer	55–60	Uni (90%)	Completely solid or with large solid component(s) and anechoic cystic fluid; average, 50 mm	Well-vascularized ovoid or sausage-shaped structure; normal ovarian tissue adjacent in 50%	3/4		191

All example images in this table are reproduced from the cited references in *Ultrasound in Obstetrics and Gynecology*. Color score indicates amount of blood flow within lesion, classified as no detectable flow (color score, 1), minimal flow (color score, 2), moderate flow (color score, 3) or abundant flow (color score, 4); scores in parentheses are less frequent. \*Yolk-sac tumor is also known as 'endodermal sinus tumor'. †Heremans *et al.* (pers. comm.). ‡Virgilio *et al.* (pers. comm.). §Ciccarone *et al.* (pers. comm.). ¶Landolfo *et al.* (pers. comm.). AFP, alpha-fetoprotein; Bi, bilateral; CA 125, cancer antigen 125; CA 15-3, cancer antigen 15-3; CA 19-9, carbohydrate antigen 19-9; CEA, carcinoembryonic antigen; hCG, human chorionic gonadotropin; LDH, lactate dehydrogenase; Ref, reference; Uni, unilateral.

preoperative diagnosis of ovarian tumors is presented in Table 2.

As many ovarian masses can be recognized relatively easily, the IOTA group also proposed four 'Simple Descriptors' of the features typical of common benign lesions and two suggestive of malignancy, which can give an 'instant diagnosis' and reflect the pattern recognition that is a key part of ultrasonography. These are applicable to about 43% of adnexal masses<sup>47</sup>. A three-step strategy, consisting of the sequential use of Simple Descriptors, Simple Rules and subjective assessment by an expert, had high accuracy for discriminating between benign and malignant adnexal lesions<sup>47</sup>. A systematic review and meta-analysis reported better performance of the IOTA Simple Rules and the IOTA LR2 model compared with all other scoring systems, including the RMI<sup>48</sup>. Besides confirming these findings, another meta-analysis highlighted that a two-step approach, with the IOTA Simple Rules as the first step and subjective assessment by an expert for inconclusive tumors as the second step, matched the test performance of expert ultrasound examiners<sup>11</sup>. The IOTA Simple Rules have been integrated into several national clinical guidelines for the evaluation and management of adnexal masses<sup>49,50</sup> and they were considered the main diagnostic strategy<sup>51</sup> as part of a first international consensus report for the assessment of adnexal masses.

A randomized controlled trial assessing surgical intervention rates and the oncologic safety of decision-making processes using on an RMI-based protocol developed by the British Royal College of Obstetricians and Gynaecologists (RCOG) *vs* triage using the IOTA Simple Rules<sup>52</sup> showed that the IOTA protocol resulted in lower surgical intervention rates compared with the RMI-based RCOG protocol. The IOTA Simple Rules did not result in more cases in which a diagnosis of cancer was delayed. It was found that the addition of biomarkers such as serum CA 125 and HE4 when using the IOTA Simple Rules, with or without subjective assessment by an expert sonographer, offered no additional diagnostic advantage for the characterization of ovarian masses, but was more costly than a three-step strategy based on the sequential use of the IOTA Simple Descriptors, Simple Rules and expert evaluation<sup>53,54</sup>.

The IOTA group have also developed the Assessment of Different Neoplasias in the adneXa (ADNEX) model. This multiclass prediction model is the first risk model to differentiate between benign and malignant tumors, whilst also offering subclassification of any malignancy into borderline tumors, Stage-I and Stage-II–IV primary cancers and secondary metastatic tumors. The IOTA ADNEX model was developed and validated using parameters collected by experienced ultrasound examiners<sup>36</sup>. Several

**Table 2** Summary of main models and scoring systems for preoperative diagnosis of ovarian tumors (adapted from Van Calster *et al.*<sup>63</sup>)

Model or system: type	Predictor variables	Remarks
Simple descriptors: classification as benign or malignant	Benign descriptor (BD) 1: unilocular tumor with ground-glass echogenicity in a premenopausal woman; BD2: unilocular tumor with mixed echogenicity and acoustic shadows in a premenopausal woman; BD3: unilocular anechoic tumor with regular walls and maximum diameter of lesion < 10 cm; BD4: remaining unilocular tumors with regular walls; Malignant descriptor (MD) 1: tumor with ascites and at least moderate color Doppler blood flow in a postmenopausal woman; MD2: age > 50 years and CA 125 > 100 U/mL	No risk estimates Based on clinical, ultrasound and CA 125 information Possible to calculate result without computer
RMI: score	CA 125, menopausal status, ultrasound score based on five binary ultrasound variables (multilocular cyst, solid areas, bilateral lesions, ascites, evidence of metastases on abdominal ultrasound)	No risk estimates Based on clinical, ultrasound and CA 125 information Possible to calculate result without computer Online calculators available
Simple Rules: classification as benign, inconclusive or malignant	Classification based on 10 binary features, i.e. five benign and five malignant features: Benign features: unilocular cyst, smooth multilocular cyst with largest diameter < 100 mm, presence of solid areas with largest diameter < 7 mm, acoustic shadows, no vascularization on color Doppler Malignant features: irregular solid tumor, irregular multilocular solid tumor with largest diameter ≥ 100 mm, presence of ascites, ≥ 4 papillary projections, very strong vascularization on color Doppler	No risk estimates Classification into only three groups Based on dichotomized ultrasound features Easy to use without computer Available as smartphone app
LR2: risk model based on logistic regression	Age (years), presence of acoustic shadows, presence of ascites, presence of papillary projections with blood flow, maximum diameter of largest solid component, irregular internal cyst walls	Risk estimates Based on clinical and ultrasound information Requires computer Available as smartphone app
Simple Rules risk: risk model based on logistic regression	The 10 binary features used in the Simple Rules, type of center (oncology center <i>vs</i> other)	Risk estimates Based on dichotomized ultrasound features Developed to add risk estimates for Simple Rules Available as online calculator; available in ultrasound machines from some manufacturers
ADNEX without CA 125: risk model based on multinomial logistic regression	Age (years), maximum diameter of lesion (mm), maximum diameter of largest solid component (mm), number of papillary projections (ordinal), presence of acoustic shadows, presence of ascites, presence of more than 10 cyst locules, type of center (oncology center <i>vs</i> other)	Risk estimates Also estimates risk of four subtypes of malignancy Based on clinical and ultrasound information Subjective predictors are avoided <i>a priori</i> (e.g. color score or irregular cyst walls) Requires computer Available as smartphone app and as online calculator; available in ultrasound machines from some manufacturers
ADNEX with CA 125: risk model based on multinomial logistic regression	Same variables as for ADNEX without CA 125, and additionally serum CA 125 (IU/L)	Risk estimates Also estimates risk of four subtypes of malignancy Based on clinical, ultrasound and CA 125 information Subjective predictors are avoided <i>a priori</i> (e.g. color score or irregular cyst walls) Requires computer Available as smartphone app and as online calculator; available in ultrasound machines from some manufacturers

CA 125, cancer antigen 125.

external validation studies have shown good to excellent performance of the ADNEX model in discriminating different types of ovarian tumor, with a higher clinical value than the RMI<sup>55–61</sup>. A study aiming to validate the ADNEX model when applied by Level-II examiners has confirmed that it can be used successfully by less-experienced examiners<sup>62</sup>. A large multicenter cohort study of 4905 masses in 17 centers, comparing six different prediction models (RMI, LR2, Simple Rules, Simple Rules risk model and ADNEX model with or without CA 125), demonstrated the IOTA ADNEX model and the IOTA Simple Rules risk model to be the best models for the characterization of ovarian masses in patients who present with an adnexal lesion<sup>63</sup>.

### GI-RADS

The Gynecologic Imaging Reporting and Data System (GI-RADS) was first introduced by Amor *et al.*<sup>64</sup> in 2009 and was validated prospectively by the same team in a multicenter study 2 years later<sup>65</sup>. This reporting system quantifies the risk of malignancy into five categories: GI-RADS 1, definitively benign (estimated probability of malignancy (EPM)=0%); GI-RADS 2, very probably benign (EPM < 1%); GI-RADS 3, probably benign (EPM = 1–4%); GI-RADS 4, probably malignant (EPM = 5–20%); and GI-RADS 5, very probably malignant (EPM > 20%). More recently, several studies have demonstrated the value of the GI-RADS system for the assessment of malignant adnexal masses in women who are candidates for surgical intervention. Furthermore, the addition of GI-RADS to CA 125 improves the identification of adnexal masses at high risk of malignancy compared with using CA 125 alone<sup>66–71</sup>.

### O-RADS

The Ovarian-Adnexal Reporting and Data System (O-RADS) lexicon for ultrasound was published in 2018, providing a standardized glossary that includes all appropriate descriptors and definitions of the characteristic ultrasound appearance of normal ovaries and various adnexal lesions<sup>72,73</sup>. The O-RADS ultrasound working group developed an adnexal-mass triage system based either on the O-RADS descriptors or on the risk of malignancy assigned to the mass using the IOTA ADNEX model to classify ovarian tumors into different risk categories<sup>74</sup>. However, to date, neither the triage system nor the O-RADS descriptors have been externally validated. Basha *et al.*<sup>75</sup> determined the malignancy rates, validity and reliability of the O-RADS approach when applied to a database of 647 adnexal masses collected before the development of the O-RADS system. In this retrospective study, the O-RADS system had significantly higher sensitivity than did the GI-RADS system and the IOTA Simple Rules, with a non-significant slightly lower specificity compared with both GI-RADS and IOTA Simple Rules, and with similar reliability.

### Statements on ultrasonography (Statements 1–6)

- Subjective assessment by expert (Level-III) ultrasound examiners has the best performance to distinguish between benign and malignant ovarian tumors.
  - Level of evidence: 1a
  - Grade of statement: A
  - Consensus: yes, 95% ( $n=19$ ); no, 0% ( $n=0$ ); abstain, 5% ( $n=1$ )
- If an expert ultrasound examiner is not available, the use of ultrasound-based diagnostic models can assist clinicians to distinguish between benign and malignant ovarian tumors.
  - Level of evidence: 2a
  - Grade of statement: B
  - Consensus: yes, 90% ( $n=18$ ); no, 0% ( $n=0$ ); abstain, 10% ( $n=2$ )
- Ultrasound-based diagnostic models (IOTA Simple Rules risk model or IOTA ADNEX model) are preferable to CA 125 level, HE4 level or ROMA as they are superior in distinguishing between benign and malignant ovarian tumors.
  - Level of evidence: 2b
  - Grade of statement: B
  - Consensus: yes, 95% ( $n=19$ ); no, 0% ( $n=0$ ); abstain, 5% ( $n=1$ )
- The IOTA ADNEX model and the IOTA Simple Rules risk model are recommended as they outperform existing morphological scoring systems, including the RMI.
  - Level of evidence: 1b
  - Grade of statement: A
  - Consensus: yes, 95% ( $n=19$ ); no, 0% ( $n=0$ ); abstain, 5% ( $n=1$ )
- The IOTA ADNEX model is a multiclass model and is helpful to differentiate between benign tumors, borderline tumors, early- or advanced-stage ovarian cancer and secondary metastatic tumors.
  - Level of evidence: 3b
  - Grade of statement: C
  - Consensus: yes, 85% ( $n=17$ ); no, 0% ( $n=0$ ); abstain, 15% ( $n=3$ )
- The threshold risk of there being a secondary metastatic tumor (as predicted by the IOTA ADNEX model), above which additional investigations to detect the primary organ of origin should be triggered, is 10%.
  - Level of evidence: 5
  - Grade of statement: D
  - Consensus: 5% threshold, 10% ( $n=2$ ); 10% threshold, 75% ( $n=15$ ); 15% threshold, 0% ( $n=0$ ); 20% threshold, 0% ( $n=0$ ); abstain, 15% ( $n=3$ )

Levels of evidence and grades are described in Appendix 2.

## Tumor markers

According to a systematic quantitative review assessing the accuracy of CA 125 level in the diagnosis of benign, borderline and malignant ovarian tumors, CA 125 is the best available single-protein biomarker identified to date<sup>76</sup>. Although it lacks sensitivity and specificity for early stages of the disease and has a relatively low specificity overall, it can help direct treatment options in patients with suspicious ovarian masses. Pooled analyses have highlighted that a high body mass index and ethnicity might influence CA 125 levels, representing an additional diagnostic challenge<sup>77</sup>. Other factors that influence CA 125 levels are the age of the patient, pregnancy, inflammatory processes and the presence of fibroids or endometriosis<sup>77–80</sup>.

Multiple studies, including meta-analyses, have highlighted the role of HE4 as a potential complement to CA 125, especially in differentiating benign endometriotic and inflammatory lesions in younger women<sup>25,81–103</sup>. Additional tumor markers (as in the ROMA test) have failed to improve significantly the discrimination between benign and malignant masses compared with CA 125 alone<sup>53,81,84,91,96–109</sup>. The combination of a more extended tumor marker profile, including the addition of carcinoembryonic antigen (CEA) and/or carbohydrate antigen (CA 19-9) to CA 125, is useful mainly for differentiating between metastatic tumors from the gastrointestinal tract or pancreas and primary ovarian malignancy<sup>110–113</sup>.

### Statements on tumor markers (Statements 7–12)

7. CA 125 is the best single-protein biomarker for the preoperative characterization of ovarian tumors. However, it is not useful as a screening test for ovarian cancer.
  - Level of evidence: 2b
  - Grade of statement: B
  - Consensus: yes, 95% ( $n = 19$ ); no, 0% ( $n = 0$ ); abstain, 5% ( $n = 1$ )
8. Neither HE4 nor ROMA improves the discrimination between benign and malignant masses compared with CA 125 alone.
  - Level of evidence: 2b
  - Grade of statement: B
  - Consensus: yes, 70% ( $n = 14$ ); no, 0% ( $n = 0$ ); abstain, 30% ( $n = 6$ )
9. CA 125 does not increase the performance of ultrasound-based risk models to distinguish between benign and malignant tumors.
  - Level of evidence: 2b
  - Grade of statement: B
  - Consensus: yes, 60% ( $n = 12$ ); no, 10% ( $n = 2$ ); abstain, 30% ( $n = 6$ )
10. CA 125 is helpful as a biomarker in cases of suspected malignancy and it helps to distinguish between

subtypes of malignant tumors, such as borderline and early- and advanced-stage primary ovarian cancers and secondary metastatic tumors.

- Level of evidence: 2b
  - Grade of statement: B
  - Consensus: yes, 90% ( $n = 18$ ); no, 5% ( $n = 1$ ); abstain, 5% ( $n = 1$ )
11. CEA may be useful in specific cases to differentiate between primary ovarian cancer and secondary (ovarian) tumors.
    - Level of evidence: 3b
    - Grade of statement: C
    - Consensus: yes, 90% ( $n = 18$ ); no, 0% ( $n = 0$ ); abstain, 10% ( $n = 2$ )
  12. CA 19-9 can help to differentiate secondary metastatic tumors in the ovary.
    - Level of evidence: 3b
    - Grade of statement: C
    - Consensus: yes, 75% ( $n = 15$ ); no, 5% ( $n = 1$ ); abstain, 20% ( $n = 4$ )

Levels of evidence and grades are described in Appendix 2.

## Magnetic resonance imaging/computed tomography/positron emission tomography-computed tomography

### Magnetic resonance imaging

Several reports have found that magnetic resonance imaging (MRI), alone or in combination with computed tomography (CT), predicts accurately the presence of peritoneal carcinomatosis in patients undergoing preoperative evaluation for cytoreductive surgery, particularly when the assessment is carried out by an experienced radiologist<sup>114–117</sup>. Recently, a prospective study reported higher specificity of the IOTA LR2 model compared with subjective interpretation of MRI findings by an experienced radiologist, as well as similar sensitivities for both imaging modalities for discriminating between benign and malignant tumors<sup>118</sup>. The addition of diffusion-weighted techniques to conventional imaging modalities has been shown in multiple pooled studies to increase diagnostic accuracy in discriminating between benign tumors and ovarian cancer, especially in the Caucasian population, with data even suggesting a value in predicting resectability<sup>119–123</sup>. However, the true extent of such a benefit needs to be validated further in multicenter, large-scale prospective randomized studies, which are currently being designed or underway<sup>121</sup>. The addition of quantitative dynamic contrast-enhanced MRI to diffusion-weighted imaging and anatomical MRI sequences and the development of a 5-point scoring system (O-RADS MRI score) is another modern diagnostic development with promising potential for the differentiation between benign and malignant adnexal masses in cases in which ultrasound is unable to arrive at a clear diagnosis (i.e. indeterminate masses). When this technique

is enhanced with volume quantification, it can help to discriminate between Type-I and Type-II epithelial ovarian cancers<sup>124–130</sup>. However, there are only limited data available on the impact of these modern MRI techniques on clinical decision-making and further studies are needed, with larger sample populations<sup>131</sup>.

### Computed tomography

Dedicated multidetector CT protocols with standardized peritoneal carcinomatosis index forms are the most common diagnostic tool used in routine clinical practice to assess the extent of tumor dissemination and the presence of peritoneal carcinomatosis<sup>132–136</sup>. A radiological peritoneal carcinomatosis index applied at preoperative CT within an expert setting has been shown to have low performance scores as a triage test to identify patients who are likely to have complete cytoreduction to no macroscopic residual disease<sup>137</sup>. On retrospective analysis, preoperative CT imaging showed high specificity but rather low sensitivity in detecting tumor involvement at key sites in ovarian cancer surgery<sup>136</sup>. Multiple studies that have attempted to cross-validate the accuracy of CT scans in predicting unresectable disease and incomplete cytoreduction have shown a substantial drop in accuracy rates when attempts have been made to validate them in other cohorts<sup>138–145</sup>. Thus, CT should not be used as the sole tool to predict the resectability of peritoneal carcinomatosis and exclude patients from surgery; rather, the full clinical context should be taken into account. Its widespread availability makes CT useful as a first-line diagnostic tool to identify patients who should not be selected for cytoreductive surgery, such as those with large/multifocal intraparenchymatous distant metastases, acute thromboembolic events or secondary metastatic tumors that limit the prognosis. The role of radiomics as an additional quantitative mathematical segmentation of conventional preoperative CT images has shown some promising results in preliminary studies; however, larger studies are necessary for validation before this technique is implemented in clinical practice<sup>146</sup>.

### Positron emission tomography-computed tomography

Positron emission tomography-computed tomography (PET-CT) may be useful in differentiating malignant from borderline or benign ovarian tumors, with the limitation that its diagnostic performance can be impacted negatively by certain tumor histological subtypes, due to the lower fluorodeoxyglucose uptake in clear-cell and mucinous invasive subtypes<sup>147–152</sup>. PET-CT can also play a role as an additional technique in the diagnosis of lymph-node metastases, especially outside the abdominal cavity, or in characterizing unclear lesions in key areas that would alter clinical management, for example chest lesions<sup>153–155</sup>. However, PET-CT does not seem to be a relevant additional diagnostic modality for the true

extent of peritoneal spread of ovarian cancer, specifically bowel and mesenteric serosa, and therefore fails to predict resectability in those key sites, especially in the presence of low-volume disease<sup>156</sup>. Furthermore, PET-CT has been shown to have a low diagnostic value in differentiating borderline from benign tumors and should therefore not be used in clinical decision-making processes in that context, especially when considering fertility-sparing procedures<sup>147,148,152</sup>.

### Statements on MRI, CT and PET-CT (Statements 13–17)

13. MRI with the inclusion of the functional sequences, dynamic contrast-enhanced and diffusion-weighted MRI, is not a first-line tool but may be used as a second-line tool after ultrasonography to further differentiate between benign, malignant and borderline masses.
  - Level of evidence: 2a
  - Grade of statement: B
  - Consensus: yes, 100% ( $n=20$ ); no, 0% ( $n=0$ ); abstain, 0% ( $n=0$ )
14. PET-CT and whole-body diffusion MRI as a second step can help to detect non-ovarian origin of secondary metastatic tumors if suspicions are raised by the initial ultrasound examination.
  - Level of evidence: 4
  - Grade of statement: C
  - Consensus: yes, 90% ( $n=18$ ); no, 0% ( $n=0$ ); abstain, 10% ( $n=2$ )
15. PET-CT cannot differentiate reliably between borderline and benign tumors.
  - Level of evidence: 4
  - Grade of statement: C
  - Consensus: yes, 95% ( $n=19$ ); no, 0% ( $n=0$ ); abstain, 5% ( $n=1$ )
16. Imaging alone cannot detect reliably the entire extent of either peritoneal carcinomatosis (especially in cases of small-volume carcinomatosis) or mesenteric and bowel serosal involvement.
  - Level of evidence: 3b
  - Grade of statement: B
  - Consensus: yes, 85% ( $n=17$ ); no, 5% ( $n=1$ ); abstain, 10% ( $n=2$ )
17. Imaging alone should not be used for surgical decision-making in terms of the prediction of peritoneal tumor resectability.
  - Level of evidence: 3b
  - Grade of statement: B
  - Consensus: yes, 80% ( $n=16$ ); no, 15% ( $n=3$ ); abstain, 5% ( $n=1$ )

Levels of evidence and grades are described in Appendix 2.

### Circulating cell-free DNA and circulating tumor cells

Circulating cell-free DNA and circulating tumor cells as non-invasive cancer biomarkers and in non-invasive biopsy (sometimes called ‘liquid biopsy’) have been investigated in multiple studies<sup>157–170</sup>. DNA methylation patterns in cell-free DNA show potential to detect a proportion of ovarian cancers up to 2 years in advance of diagnosis. They may potentially guide personalized treatment, even though validation studies are lacking. The prospective use of novel collection vials, which stabilize blood cells and reduce background DNA contamination in serum/plasma samples, will facilitate the clinical implementation of liquid biopsy analyses<sup>160</sup>. A prospective evaluation of the potential of cell-free DNA for the diagnosis of primary ovarian cancer using chromosomal instability as a read-out suggested that this might be a promising method to increase the specificity of the presurgical prediction of malignancy in patients with adnexal masses<sup>168</sup>. However, even though these circulating biomarkers play a key role in understanding metastasis and tumorigenesis and provide comprehensive insight into tumor evolution and dynamics during treatment and disease progression, they still have not been established as part of routine clinical practice<sup>157–159</sup>.

One meta-analysis suggested that quantitative analysis of cell-free DNA has unsatisfactory sensitivity but acceptable specificity for the diagnosis of ovarian cancer<sup>170</sup>. In a more recent meta-analysis, cell-free DNA appeared to be slightly better than CA 125 and similar to HE4 with respect to its diagnostic ability

to discriminate individuals with from those without ovarian cancer<sup>163</sup>. Nevertheless, the diagnostic value of cell-free DNA in ovarian cancer patients remains unclear and the data should be interpreted with caution. Further large-scale prospective studies are strongly recommended to validate the potential applicability of using circulating cell-free DNA, alone or in combination with conventional markers, as a diagnostic biomarker for ovarian cancer, and to explore potential factors that may influence the accuracy of ovarian cancer diagnosis<sup>170</sup>.

#### Statement on circulating cell-free DNA and tumor cells (Statement 18)

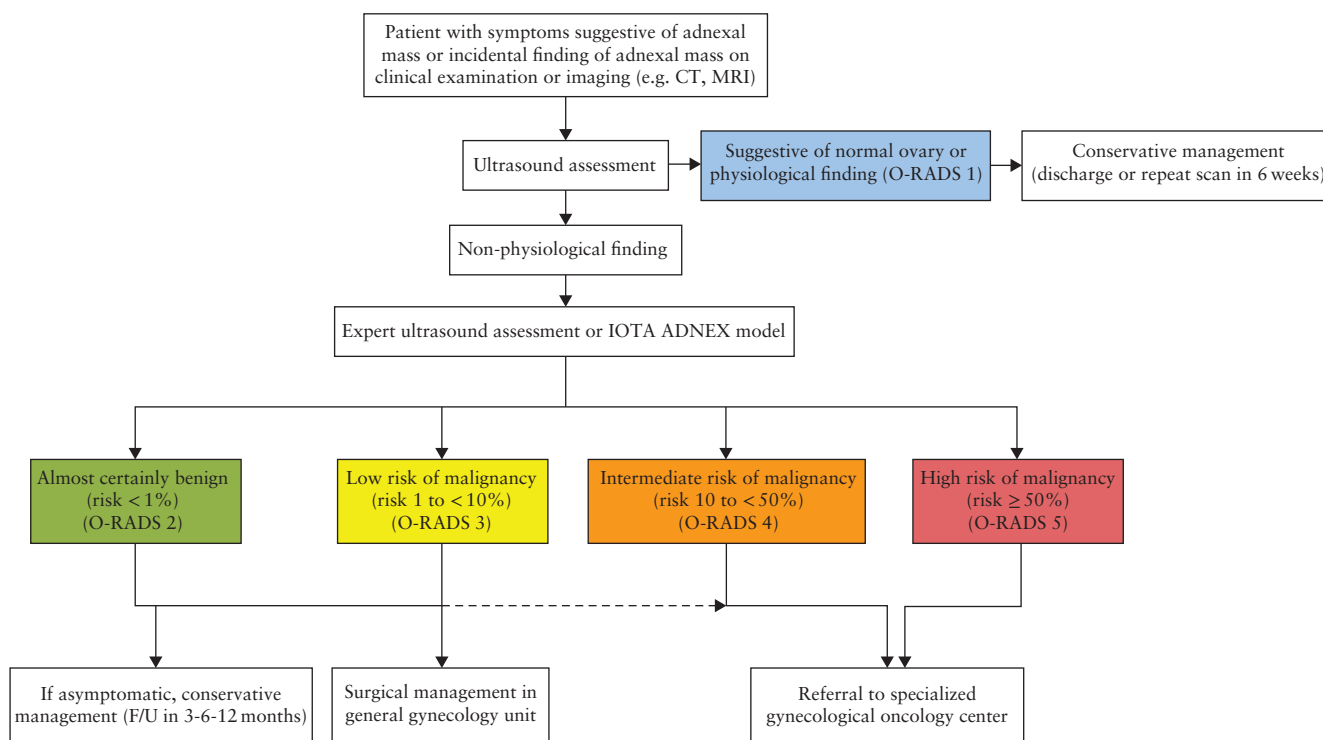
18. Circulating cell-free DNA and circulating tumor cells should not yet be used in routine clinical practice to differentiate between benign and malignant ovarian masses.

- Level of evidence: 4
- Grade of statement: C
- Consensus: yes, 85% (*n* = 17); no, 5% (*n* = 1); abstain, 10% (*n* = 2)

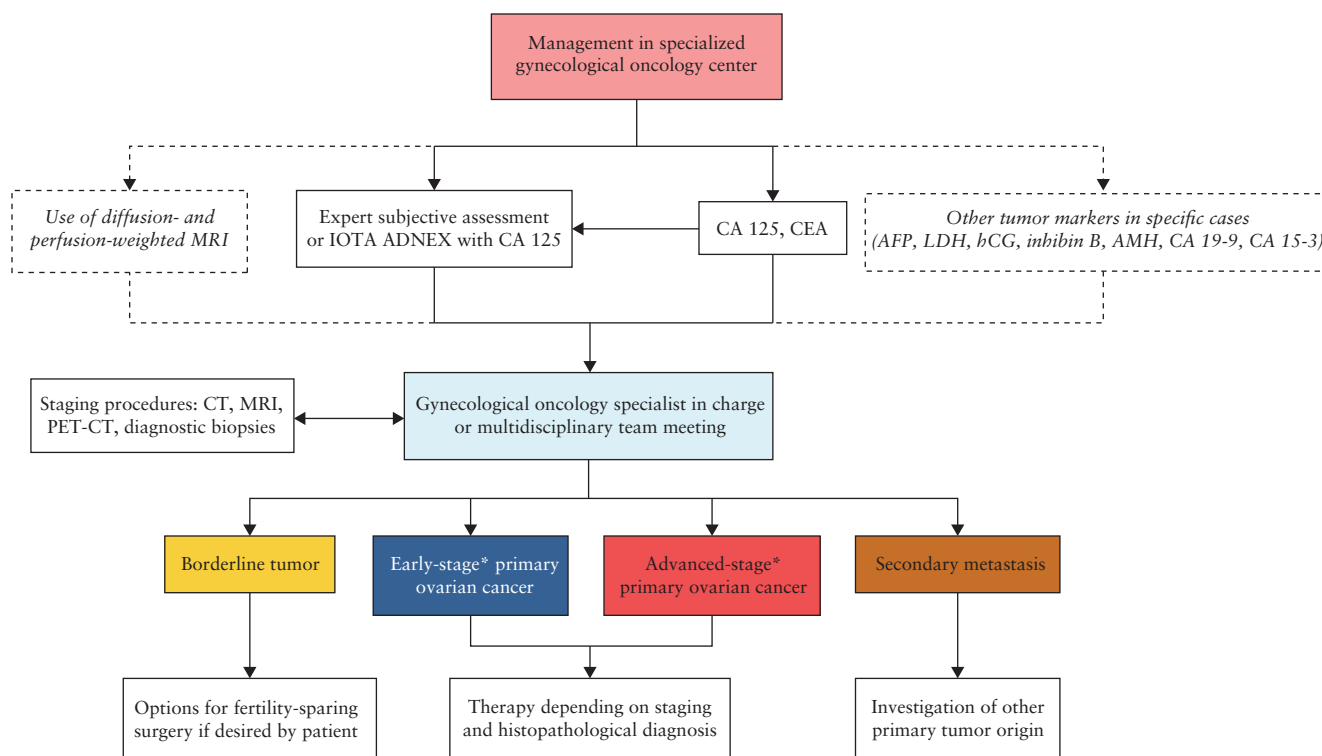
Levels of evidence and grades are described in Appendix 2.

### OVERVIEW OF CONSENSUS

The experts also reached a consensus on a flowchart describing steps recommended to distinguish between benign and malignant tumors (Figure 2) and to direct



**Figure 2** Flowchart of steps recommended to distinguish between benign and malignant tumors and to direct patients towards appropriate treatment pathway. CT, computed tomography; F/U, follow-up; IOTA ADNEX, International Ovarian Tumour Analysis group Assessment of Different NEoplasias in the adneXa; MRI, magnetic resonance imaging; O-RADS, Ovarian-Adnexal Reporting and Data System.



**Figure 3** Flowchart of steps necessary to differentiate between subgroups of malignancy and extent of disease within gynecological oncology centers. \*Early stage and advanced stage might differ according to different ADNEX models (Stage I *vs* Stages II–IV) and oncologically (Stages I–II *vs* Stages III–IV). AFP, alpha-fetoprotein; AMH, anti-Müllerian hormone; CA 125, cancer antigen 125; CA 15-3, cancer antigen 15-3; CA 19-9, carbohydrate antigen 19-9; CEA, carcinoembryonic antigen; CT, computed tomography; hCG, human chorionic gonadotropin; IOTA ADNEX, International Ovarian Tumour Analysis group Assessment of Different NEoplasias in the adneXa; LDH, lactate dehydrogenase; MRI, magnetic resonance imaging; PET-CT, positron emission tomography-computed tomography.

patients towards appropriate treatment pathways. Ultrasonography is recommended as a first step to stratify patients with symptoms suggestive of an adnexal mass, and in those with an incidental finding of an adnexal mass on imaging. If the scan rules out normal ovaries and physiological changes (i.e. rules out O-RADS 1), the IOTA ADNEX model could be applied as a next step in order to determine the risk of malignancy. Any ultrasonographic examination in the case of a suspected ovarian mass should be performed by an expert sonographer. The resulting classification of the lesion into one of the O-RADS categories (2–5) can further guide the management and selection of patients for referral to a dedicated gynecological oncology center.

A consensus was also reached on further steps necessary to differentiate between subgroups of malignancy and extent of disease within gynecological oncology centers (Figure 3). Ultrasound assessment by an expert or application of the IOTA ADNEX model in combination with the tumor marker profile (CA 125 and CEA, complemented with other markers in specific cases) can often indicate the specific subtype of malignancy. If available, diagnosis of the primary lesion can be confirmed with diffusion- and perfusion-weighted MRI, especially in cases in which fertility-sparing surgery is considered. A CT scan of chest, abdomen and pelvis is mandatory before planned surgery for presumed malignancy, in order to exclude secondary cancers, thromboembolic events,

and multifocal intraparenchymal distant metastases that would preclude operability. The final management and treatment journey of the patient should be determined within an expert multidisciplinary setting, taking into account both the diagnostic findings and the overall patient profile, including symptoms, patient preferences and prior surgical, medical and reproductive history, with the ultimate aim of defining an individualized approach for every patient.

## AUTHORS

**D. Timmerman**<sup>®</sup> (corresponding author: dirk.timmerman@uzleuven.be), Department of Development and Regeneration, KU Leuven, Leuven, Belgium; Department of Obstetrics and Gynecology, University Hospitals Leuven, Leuven, Belgium

**F. Planchamp**, Clinical Research Unit, Institut Bergonie, Bordeaux, France

**T. Bourne**<sup>®</sup>, Department of Development and Regeneration, KU Leuven, Leuven, Belgium; Department of Obstetrics and Gynecology, University Hospitals Leuven, Leuven, Belgium; Department of Metabolism, Digestion and Reproduction, Queen Charlotte's & Chelsea Hospital, Imperial College, London, UK

**C. Landolfo**<sup>®</sup>, Department of Woman, Child and Public Health, Fondazione Policlinico Universitario A. Gemelli IRCCS, Rome, Italy

**A. du Bois**, Department of Gynaecology and Gynaecological Oncology, Evangelische Kliniken Essen-Mitte, Essen, Germany

**L. Chiva**, Department of Gynaecology and Obstetrics, University Clinic of Navarra, Madrid, Spain

**D. Cibula**, Department of Obstetrics and Gynaecology, First Faculty of Medicine, Charles University, General University Hospital in Prague, Prague, Czech Republic

**N. Concin**, Department of Gynaecology and Gynaecological Oncology, Evangelische Kliniken Essen-Mitte, Essen, Germany; Department of Obstetrics and Gynaecology, Medical University of Innsbruck, Innsbruck, Austria

**D. Fischerova**, Department of Obstetrics and Gynaecology, First Faculty of Medicine, Charles University, General University Hospital in Prague, Prague, Czech Republic

**W. Froyman**, Department of Obstetrics and Gynaecology, University Hospitals KU Leuven, Leuven, Belgium

**G. Gallardo**, Department of Radiology, University Clinic of Navarra, Madrid, Spain

**B. Lemley**, Patient Representative, President of Kræfti Underlivet (KIU), Denmark; Chair Clinical Trial Project of the European Network of Gynaecological Cancer Advocacy Groups, ENGAGE

**A. Loft**, Department of Clinical Physiology, Nuclear Medicine & PET, Rigshospitalet, Copenhagen University Hospital, Copenhagen, Denmark

**L. Mereu**, Department of Gynecology and Obstetrics, Gynecologic Oncology Unit, Santa Chiara Hospital, Trento, Italy

**P. Morice**, Department of Gynaecological Surgery, Institut Gustave Roussy, Villejuif, France

**D. Querleu**, Division of Gynecologic Oncology, Fondazione Policlinico Universitario A Gemelli IRCCS, Rome, Italy; Department of Obstetrics and Gynecologic Oncology, University Hospital, Strasbourg, France

**A. C. Testa**, Department of Woman, Child and Public Health, Fondazione Policlinico Universitario A. Gemelli IRCCS, Rome, Italy; Institute of Obstetrics and Gynecology, Università Cattolica del Sacro Cuore, Rome, Italy

**I. Vergote**, Department of Obstetrics and Gynaecology and Gynaecologic Oncology, University Hospital Leuven, Leuven Cancer Institute, Leuven, Belgium

**V. Vandecaveye**, Department of Radiology, University Hospitals Leuven, Leuven Belgium; Division of Translational MRI, Department of Imaging & Pathology KU Leuven, Leuven, Belgium

**G. Scambia**, Department of Woman, Child and Public Health, Fondazione Policlinico Universitario A. Gemelli IRCCS, Rome, Italy; Institute of Obstetrics and Gynecology, Università Cattolica del Sacro Cuore, Rome, Italy

**C. Fotopoulou**, Department of Gynecologic Oncology, Hammersmith Hospital, Imperial College, London, UK

Initiated through ESGO, the decision to develop multidisciplinary consensus statements was made jointly

by ESGO, ISUOG, IOTA and ESGE. ESGO provided administrative support. ESGO, ISUOG, IOTA and ESGE are non-profit-making professional societies. The development group (including all authors) is responsible collectively for the decision to submit for publication. Christina Fotopoulou (chair), Dirk Timmerman (chair) and François Planchamp (methodologist) wrote the first draft of the manuscript. All other contributors actively gave personal input, reviewed the manuscript and gave final approval before submission.

## CITATION

This Consensus Statement should be cited as: 'Timmerman D, Planchamp F, Bourne T, Landolfo C, du Bois A, Chiva L, Cibula D, Concin N, Fischerova D, Froyman W, Gallardo G, Lemley B, Loft A, Mereu L, Morice P, Querleu D, Testa AC, Vergote I, Vandecaveye V, Scambia G, Fotopoulou C. ESGO/ISUOG/IOTA/ESGE Consensus Statement on preoperative diagnosis of ovarian tumors. *Ultrasound Obstet Gynecol* 2021. DOI: 10.1002/uog.23635.'

## ACKNOWLEDGMENTS

The authors thank ESGO, ISUOG, IOTA and ESGE for their support. We wish also to express sincere gratitude to Maciej Malecki (University Hospital Leuven, Leuven, Belgium) for providing technical support during the conference call.

## Funding

All costs relating to the development process were covered from ESGO, ISUOG, IOTA and ESGE funds. There was no external funding of the development process or manuscript production.

## Disclosures

D.T.: senior investigator for FWO (Fund for Scientific Research Flanders) and research sponsored by Roche Diagnostics. KU Leuven has consultancy agreements with GE Healthcare, Samsung Healthcare, GSK and Canon. T.B.: research sponsored by Roche Diagnostics, Samsung Medison and Illumina, and grants for traveling from Samsung Medison. L.C.: advisory boards for AstraZeneca, GSK, Takeda and Roche. D.C.: advisory boards for Genmab, AstraZeneca, Roche and Sotio. N.C.: advisory boards for AstraZeneca, Seattle Genetics, Mersana and eTheRNA Immunotherapies NV, grants for traveling from Roche, Genmab and Amgen, and educational fees from MSD and Medscape Oncology. A.d.B.: advisory boards for Roche, AstraZeneca, GSK/Tesaro, BIOCAD, Clovis, Genmab/Seattle Genetics, Pfizer and Amgen, and grants for traveling from Roche and AstraZeneca. I.V.: consulting activities for Amgen, AstraZeneca, Clovis



Oncology, Carrick Therapeutics, Debiopharm International SA, Deciphera Pharmaceuticals, Elevar Therapeutics, F. Hoffmann-La Roche Ltd, Genmab, GSK, Immunogen Inc, Medical University of Vienna, Mersana, Millenium Pharmaceuticals, MSD, Novocure, Octimet Oncology NV, Oncinvent AS, Pharmamar, Sotio a.s. Prague, Tesaro Inc, Verastem Oncology and Zentalis, contracted research (via KU Leuven) from Oncinvent AS and Genmab, grants (corporate sponsored research) from Amgen and Roche, and accommodation/travel expenses from Amgen, MSD, Tesaro, AstraZeneca and Roche. C.F.: advisory boards for Roche, GSK, Tesaro, AZ/MSD, Clovis, Sequana and Ethicon, and grants for traveling from GSK and Roche. F.P., C.L., D.F., W.F., G.G., B.L., A.L., L.M., P.M., D.Q., A.C.T., V.V. and G.S. report no conflicts of interest.

## REFERENCES

- Querleu D, Planchamp F, Chiva L, Fotopoulou C, Barton D, Cibula D, Aletri G, Carinelli S, Creutzberg C, Davidson B, Harter P, Lundvall L, Marth C, Morice P, Rafii A, Ray-Coquard I, Rockall A, Sessa C, van der Zee A, Vergote I, duBois A. European Society of Gynaecological Oncology (ESGO) Guidelines for Ovarian Cancer Surgery. *Int J Gynecol Cancer* 2017; 27: 1534–1542.
- Woo YL, Kyrgiou M, Bryant A, Everett T, Dickinson HO. Centralisation of services for gynaecological cancer. *Cochrane Database Syst Rev* 2012; 14: CD007945.
- Engelen MJ, Kos HE, Willems PH, Aalders JG, de Vries EG, Schaapveld M, Otter R, van der Zee AG. Surgery by consultant gynecologic oncologists improves survival in patients with ovarian carcinoma. *Cancer* 2006; 106: 589–598.
- Froyman W, Landolfo C, De Cock B, Wynants L, Sladkevicius P, Testa AC, Van Holsbeke C, Domali E, Fruscio R, Epstein E, Dos Santos Bernardo MJ, Franchi D, Kudla MJ, Chiappa V, Alcazar JL, Leone FPG, Buonomo F, Hochberg L, Coccia ME, Guerriero S, Deo N, Jokubkiene L, Kaijser J, Coosemans A, Vergote I, Verbakel JY, Bourne T, Van Calster B, Valentin L, Timmerman D. Risk of complications in patients with conservatively managed ovarian tumours (IOTA5): a 2-year interim analysis of a multicentre, prospective, cohort study. *Lancet Oncol* 2019; 20: 448–458.
- du Bois A, Rochon J, Pfisterer J, Hoskins WJ. Variations in institutional infrastructure, physician specialization and experience, and outcome in ovarian cancer: a systematic review. *Gynecol Oncol* 2009; 112: 422–436.
- Elit LM, Bondy SJ, Paszat LP, Holowaty EJ, Thomas GM, Stukel TA, Levine MN. Surgical outcomes in women with ovarian cancer. *Can J Surg* 2008; 51: 346–354.
- Vernooij F, Heintz P, Witteveen E, van der Graaf Y. The outcomes of ovarian cancer treatment are better when provided by gynecologic oncologists and in specialized hospitals: a systematic review. *Gynecol Oncol* 2007; 105: 801–812.
- Kaijser J, Vandecaveye V, Deroose CM, Rockall A, Thomassin-Naggara I, Bourne T, Timmerman D. Imaging techniques for the pre-surgical diagnosis of adnexal tumours. *Best Pract Res Clin Obstet Gynaecol* 2014; 28: 683–695.
- Valentin L, Hagen B, Tingulstad S, Eik-Nes S. Comparison of 'pattern recognition' and logistic regression models for discrimination between benign and malignant pelvic masses: a prospective cross validation. *Ultrasound Obstet Gynecol* 2001; 18: 357–365.
- Timmerman D. The use of mathematical models to evaluate pelvic masses; can they beat an expert operator? *Best Pract Res Clin Obstet Gynaecol* 2004; 18: 91–104.
- Meys EM, Kaijser J, Kruitwagen RF, Slangen BF, Van Calster B, Aertgeerts B, Verbakel JY, Timmerman D, Van Gorp T. Subjective assessment versus ultrasound models to diagnose ovarian cancer: A systematic review and meta-analysis. *Eur J Cancer* 2016; 58: 17–29.
- Valentin L. Prospective cross-validation of Doppler ultrasound examination and gray-scale ultrasound imaging for discrimination of benign and malignant pelvic masses. *Ultrasound Obstet Gynecol* 1999; 14: 273–283.
- Timmerman D, Schwarzler P, Collins WP, Claerhout F, Coenen M, Amant F, Vergote I, Bourne TH. Subjective assessment of adnexal masses with the use of ultrasonography: an analysis of interobserver variability and experience. *Ultrasound Obstet Gynecol* 1999; 13: 11–16.
- Yazbek J, Raju SK, Ben-Nagi J, Holland TK, Hillaby K, Jurkovic D. Effect of quality of gynaecological ultrasonography on management of patients with suspected ovarian cancer: a randomised controlled trial. *Lancet Oncol* 2008; 9: 124–131.
- Education and Practical Standards Committee, European Federation of Societies for Ultrasound in Medicine and Biology. Minimum training recommendations for the practice of medical ultrasound. *Ultraschall Med* 2006; 27: 79–105.
- Jacobs I, Oram D, Fairbanks J, Turner J, Frost C, Grudzinskas JG. A risk of malignancy index incorporating CA 125, ultrasound and menopausal status for the accurate preoperative diagnosis of ovarian cancer. *Br J Obstet Gynaecol* 1990; 97: 922–929.
- Chacon E, Dasi J, Caballero C, Alcazar JL. Risk of Ovarian Malignancy Algorithm versus Risk Malignancy Index-I for Preoperative Assessment of Adnexal Masses: A Systematic Review and Meta-Analysis. *Gynecol Obstet Invest* 2019; 84: 591–598.
- Westwood M, Ramaekers B, Lang S, Grimm S, Deshpande S, de Kock S, Armstrong N, Joore M, Kleijnen J. Risk scores to guide referral decisions for people with suspected ovarian cancer in secondary care: a systematic review and cost-effectiveness analysis. *Health Technol Assess* 2018; 22: 1–264.
- Khoiwal K, Bahadur A, Kumari R, Bhattacharya N, Rao S, Chaturvedi J. Assessment of Diagnostic Value of Serum Ca-125 and Risk of Malignancy Index Scoring in the Evaluation of Adnexal Masses. *J Midlife Health* 2019; 10: 192–196.
- Dochez V, Randet M, Renaudeau C, Dimet J, Le Thuaut A, Winer N, Thubert T, Vaucel E, Caillon H, Ducarme G. Efficacy of HE4, CA125, Risk of Malignancy Index and Risk of Ovarian Malignancy Index to Detect Ovarian Cancer in Women with Presumed Benign Ovarian Tumours: A Prospective, Multicentre Trial. *J Clin Med* 2019; 8: 1784.
- Al-Musallhi K, Al-Kindi M, Ramadhan F, Al-Rawahi T, Al-Hatali K, Mula-Abed WA. Validity of Cancer Antigen-125 (CA-125) and Risk of Malignancy Index (RMI) in the Diagnosis of Ovarian Cancer. *Oman Med J* 2015; 30: 428–434.
- Zhang S, Yu S, Hou W, Li X, Ning C, Wu Y, Zhang F, Jiao YF, Lee LTO, Sun L. Diagnostic extended usefulness of RMI: comparison of four risk of malignancy index in preoperative differentiation of borderline ovarian tumors and benign ovarian tumors. *J Ovarian Res* 2019; 12: 87.
- Bouzari Z, Yazdani S, Shirkhani Kelagar Z, Abbaszadeh N. Risk of malignancy index as an evaluation of preoperative pelvic mass. *Caspian J Intern Med* 2011; 2: 331–335.
- Chopra S, Vaishya R, Kaur J. An Evaluation of the Applicability of the Risk of Malignancy Index for Adnexal Masses to Patients Seen at a Tertiary Hospital in Chandigarh, India. *J Obstet Gynaecol India* 2015; 65: 405–410.
- Al Musallhi K, Al Kindi M, Al Aisary F, Ramadhan F, Al Rawahi T, Al Hatali K, Mula-Abed WA. Evaluation of HE4, CA-125, Risk of Ovarian Malignancy Algorithm (ROMA) and Risk of Malignancy Index (RMI) in the Preoperative Assessment of Patients with Adnexal Mass. *Oman Med J* 2016; 31: 336–344.
- Javdekar R, Maitra N. Risk of Malignancy Index (RMI) in Evaluation of Adnexal Mass. *J Obstet Gynaecol India* 2015; 65: 117–121.
- Akturk E, Karaca RE, Alanbay I, Dede M, Karasahin E, Yenen MC, Baser I. Comparison of four malignancy risk indices in the detection of malignant ovarian masses. *J Gynecol Oncol* 2011; 22: 177–182.
- Hada A, Han LP, Chen Y, Hu QH, Yuan Y, Liu L. Comparison of the predictive performance of risk of malignancy indexes 1-4, HE4 and risk of malignancy algorithm in the triage of adnexal masses. *J Ovarian Res* 2020; 13: 46.
- Anton C, Carvalho FM, Oliveira EI, Maciel GA, Baracat EC, Carvalho JP. A comparison of CA125, HE4, risk ovarian malignancy algorithm (ROMA), and risk malignancy index (RMI) for the classification of ovarian masses. *Clinics (Sao Paulo)* 2012; 67: 437–441.
- Moore RG, Brown AK, Miller MC, Skates S, Allard WJ, Verch T, Steinhoff M, Messerlian G, DiSilvestro P, Granai CO, Bast Jr RC. The use of multiple novel tumor biomarkers for the detection of ovarian carcinoma in patients with a pelvic mass. *Gynecol Oncol* 2008; 108: 402–408.
- Kaijser J, Van Gorp T, Sayasneh A, Vergote I, Bourne T, Van Calster B, Timmerman D. Differentiating stage I epithelial ovarian cancer from benign disease in women with adnexal tumors using biomarkers or the ROMA algorithm. *Gynecol Oncol* 2013; 130: 398–399.
- Timmerman D, Van Calster B, Jurkovic D, Valentin L, Testa AC, Bernard JP, Van Holsbeke C, Van Huffel S, Vergote I, Bourne T. Inclusion of CA-125 does not improve mathematical models developed to distinguish between benign and malignant adnexal tumors. *J Clin Oncol* 2007; 25: 4194–4200.
- Timmerman D, Valentin L, Bourne TH, Collins WP, Verrelst H, Vergote I. Terms, definitions and measurements to describe the sonographic features of adnexal tumors: a consensus opinion from the International Ovarian Tumor Analysis (IOTA) Group. *Ultrasound Obstet Gynecol* 2000; 16: 500–505.
- Timmerman D, Testa AC, Bourne T, Ferrazzi E, Amey L, Konstantinovic ML, Van Calster B, Collins WP, Vergote I, Van Huffel S, Valentin L. Logistic regression model to distinguish between the benign and malignant adnexal mass before surgery: a multicenter study by the International Ovarian Tumor Analysis Group. *J Clin Oncol* 2005; 23: 8794–8801.
- Timmerman D, Van Calster B, Testa A, Savelli L, Fischerova D, Froyman W, Wynants L, Van Holsbeke C, Epstein E, Franchi D, Kaijser J, Czekierdowski A, Guerriero S, Fruscio R, Leone FPG, Rossi A, Landolfo C, Vergote I, Bourne T, Valentin L. Predicting the risk of malignancy in adnexal masses based on the Simple Rules from the International Ovarian Tumor Analysis group. *Am J Obstet Gynecol* 2016; 214: 424–437.
- Van Calster B, Van Hoorde K, Valentin L, Testa AC, Fischerova D, Van Holsbeke C, Savelli L, Franchi D, Epstein E, Kaijser J, Van Belle V, Czekierdowski A, Guerriero S, Fruscio R, Lanzani C, Scala F, Bourne T, Timmerman D. Evaluating the risk of ovarian cancer before surgery using the ADNEX model to differentiate between benign, borderline, early and advanced stage invasive, and secondary metastatic tumours: prospective multicentre diagnostic study. *BMJ* 2014; 349: g5920.
- Van Holsbeke C, Van Calster B, Bourne T, Ajossa S, Testa AC, Guerriero S, Fruscio R, Lisoni AA, Czekierdowski A, Savelli L, Van Huffel S, Valentin L, Timmerman D. External validation of diagnostic models to estimate the risk of malignancy in adnexal masses. *Clin Cancer Res* 2012; 18: 815–825.
- Sayasneh A, Wynants L, Preisler J, Kaijser J, Johnson S, Stalder C, Husicka R, Abdallah Y, Raslan F, Drought A, Smith AA, Ghaem-Maghani S, Epstein E, Van Calster B, Timmerman D, Bourne T. Multicentre external validation of IOTA prediction models and RMI by operators with varied training. *Br J Cancer* 2013; 108: 2448–2454.

39. Timmerman D, Testa AC, Bourne T, Aમેયે L, Jurkovic D, Van Holsbeke C, Paladini D, Van Calster B, Vergote I, Van Huffel S, Valentin L. Simple ultrasound-based rules for the diagnosis of ovarian cancer. *Ultrasound Obstet Gynecol* 2008; **31**: 681–690.
40. Timmerman D, Aમેયે L, Fischerova D, Epstein E, Melis GB, Guerriero S, Van Holsbeke C, Savelli L, Fruscio R, Lissoni AA, Testa AC, Veldman J, Vergote I, Van Huffel S, Bourne T, Valentin L. et al. Simple ultrasound rules to distinguish between benign and malignant adnexal masses before surgery: prospective validation by IOTA group. *BMJ* 2010; **341**: e6839.
41. Hartman CA, Juliato CR, Sarian LO, Toledo MC, Jales RM, Morais SS, Pitta DD, Marussi EF, Derchain S. Ultrasound criteria and CA125 as predictive variables of ovarian cancer in women with adnexal tumors. *Ultrasound Obstet Gynecol* 2012; **40**: 360–366.
42. Alcazar JL, Pascual MA, Olartecoechea B, Graupera B, Auba M, Ajossa S, Hereter L, Julve R, Gaston B, Peddes C, Sedda F, Piras A, Saba L, Guerriero S. IOTA simple rules for discriminating between benign and malignant adnexal masses: prospective external validation. *Ultrasound Obstet Gynecol* 2013; **42**: 467–471.
43. Tantipalakorn C, Wanapirak C, Khunamornpong S, Sukpan K, Tongsong T. IOTA simple rules in differentiating between benign and malignant ovarian tumors. *Asian Pac J Cancer Prev* 2014; **15**: 5123–5126.
44. Nunes N, Ambler G, Foo X, Naftalin J, Widschwendter M, Jurkovic D. Use of IOTA simple rules for diagnosis of ovarian cancer: meta-analysis. *Ultrasound Obstet Gynecol* 2014; **44**: 503–514.
45. Ruiz de Gauna B, Rodriguez D, Olartecoechea B, Auba M, Jurado M, Gomez Roig MD, Alcazar JL. Diagnostic performance of IOTA simple rules for adnexal masses classification: a comparison between two centers with different ovarian cancer prevalence. *Eur J Obstet Gynecol Reprod Biol* 2015; **191**: 10–14.
46. Knafel A, Banas T, Nocun A, Wiechec M, Jach R, Ludwin A, Kabzinska-Turek M, Pietrus M, Pitynski K. The Prospective External Validation of International Ovarian Tumor Analysis (IOTA) Simple Rules in the Hands of Level I and II Examiners. *Ultraschall Med* 2016; **37**: 516–523.
47. Aમેયે L, Timmerman D, Valentin L, Paladini D, Zhang J, Van Holsbeke C, Lissoni AA, Savelli L, Veldman J, Testa AC, Amant F, Van Huffel S, Bourne T. Clinically oriented three-step strategy for assessment of adnexal pathology. *Ultrasound Obstet Gynecol* 2012; **40**: 582–591.
48. Kaijser J, Sayasneh A, Van Hoorde K, Ghaem-Maghani S, Bourne T, Timmerman D, Van Calster B. Presurgical diagnosis of adnexal tumours using mathematical models and scoring systems: a systematic review and meta-analysis. *Hum Reprod Update* 2014; **20**: 449–462.
49. American College of Obstetricians and Gynecologists' Committee on Practice Bulletins – Gynecology. Practice Bulletin No. 174: Evaluation and Management of Adnexal Masses. *Obstet Gynecol* 2016; **128**: e210–e226.
50. Royal College of Obstetricians and Gynaecologists. Management of suspected ovarian masses in premenopausal women. Green-top Guideline No. 62, 2011. [https://www.rcog.org.uk/globalassets/documents/guidelines/gtg\\_62.pdf](https://www.rcog.org.uk/globalassets/documents/guidelines/gtg_62.pdf) [Accessed 27 October 2020].
51. Glanc P, Benacerraf B, Bourne T, Brown D, Coleman BG, Crum C, Dodge J, Levine D, Pavlik E, Timmerman D, Ueland FR, Wolfman W, Goldstein SR. First International Consensus Report on Adnexal Masses: Management Recommendations. *J Ultrasound Med* 2017; **36**: 849–863.
52. Nunes N, Ambler G, Foo X, Naftalin J, Derdelis G, Widschwendter M, Jurkovic D. Comparison of two protocols for the management of asymptomatic postmenopausal women with adnexal tumours - a randomised controlled trial of RMI/RCOG vs Simple Rules. *Br J Cancer* 2017; **116**: 584–591.
53. Piovano E, Cavallero C, Fuso L, Viora E, Ferrero A, Gregori G, Grillo C, Macchi C, Mengozzi G, Mitidieri M, Pagano E, Zola P. Diagnostic accuracy and cost-effectiveness of different strategies to triage women with adnexal masses: a prospective study. *Ultrasound Obstet Gynecol* 2017; **50**: 395–403.
54. Alcazar JL, Pascual MA, Graupera B, Auba M, Errasti T, Olartecoechea B, Olartecoechea B, Ruiz-Zambrana A, Hereter L, Ajossa S, Guerriero S. External validation of IOTA simple descriptors and simple rules for classifying adnexal masses. *Ultrasound Obstet Gynecol* 2016; **48**: 397–402.
55. Sayasneh A, Ferrara L, De Cock B, Saso S, Al-Memari M, Johnson S, Kaijser J, Carvalho J, Husicka R, Smith A, Stalder C, Blanco MC, Ettore G, Van Calster B, Timmerman D, Bourne T. Evaluating the risk of ovarian cancer before surgery using the ADNEX model: a multicentre external validation study. *Br J Cancer* 2016; **115**: 542–548.
56. Araujo KG, Jales RM, Pereira PN, Yoshida A, de Angelo Andrade L, Sarian LO, Derchain S. Performance of the IOTA ADNEX model in preoperative discrimination of adnexal masses in a gynecological oncology center. *Ultrasound Obstet Gynecol* 2017; **49**: 778–783.
57. Meys EMJ, Jeelof LS, Achten NMJ, Slangen BFM, Lambrechts S, Kruitwagen R, Van Gorp T. Estimating risk of malignancy in adnexal masses: external validation of the ADNEX model and comparison with other frequently used ultrasound methods. *Ultrasound Obstet Gynecol* 2017; **49**: 784–792.
58. Szubert S, Wojtowicz A, Moszynski R, Zywica P, Dyczkowski K, Stachowiak A, Sajdak S, Szperek D, Alcazar JL. External validation of the IOTA ADNEX model performed by two independent gynecologic centers. *Gynecol Oncol* 2016; **142**: 490–495.
59. Van Calster B, Steyerberg EW, Bourne T, Timmerman D, Collins GS. Flawed external validation study of the ADNEX model to diagnose ovarian cancer. *Gynecol Oncol Rep* 2016; **18**: 49–50.
60. Van Calster B. External validation of ADNEX model for diagnosing ovarian cancer: evaluating performance of differentiation between tumor subgroups. *Ultrasound Obstet Gynecol* 2017; **50**: 406–407.
61. Wynants L, Timmerman D, Verbakel JY, Testa A, Savelli L, Fischerova D, Franchi D, Van Holsbeke C, Epstein E, Froyman W, Guerriero S, Rossi A, Fruscio R, Leone FP, Bourne T, Valentin L, Van Calster B. Clinical Utility of Risk Models to Refer Patients with Adnexal Masses to Specialized Oncology Care: Multicenter External Validation Using Decision Curve Analysis. *Clin Cancer Res* 2017; **23**: 5082–5090.
62. Viora E, Piovano E, Baima Poma C, Cotrino I, Castiglione A, Cavallero C, Sciarrone A, Bastonero S, Iskra L, Zola P. The ADNEX model to triage adnexal masses: An external validation study and comparison with the IOTA two-step strategy and subjective assessment by an experienced ultrasound operator. *Eur J Obstet Gynecol Reprod Biol* 2020; **247**: 207–211.
63. Van Calster B, Valentin L, Froyman W, Landolfo C, Ceusters J, Testa AC, Wynants L, Sladkevicius P, Van Holsbeke C, Domali E, Fruscio R, Epstein E, Franchi D, Kudla MJ, Chiappa V, Alcazar JL, Leone PPG, Buonomo F, Coccia ME, Guerriero S, Deo, N, Jokubkiene L, Savelli L, Fischerova D, Czekiardowski A, Kaijser J, Coosemans A, Scambia G, Vergote I, Bourne T, Timmerman D. Validation of models to diagnose ovarian cancer in patients managed surgically or conservatively: multicentre cohort study. *BMJ* 2020; **370**: m2614.
64. Amor F, Vaccaro H, Alcazar JL, Leon M, Craig JM, Martinez J. Gynecologic imaging reporting and data system: a new proposal for classifying adnexal masses on the basis of sonographic findings. *J Ultrasound Med* 2009; **28**: 285–291.
65. Amor F, Alcazar JL, Vaccaro H, Leon M, Iturra A. GI-RADS reporting system for ultrasound evaluation of adnexal masses in clinical practice: a prospective multicenter study. *Ultrasound Obstet Gynecol* 2011; **38**: 450–455.
66. Konecny J, Czekiardowski A, Florczak M, Poziemski P, Stachowicz N, Borowski D. The use of sonographic subjective tumor assessment, IOTA logistic regression model 1, IOTA Simple Rules and GI-RADS system in the preoperative prediction of malignancy in women with adnexal masses. *Ginekol Pol* 2017; **88**: 647–653.
67. Zheng H, Tie Y, Wang X, Yang Y, Wei X, Zhao X. Assessment of the diagnostic value of using serum CA125 and GI-RADS system in the evaluation of adnexal masses. *Medicine (Baltimore)* 2019; **98**: e14577.
68. Zhang T, Li F, Liu J, Zhang S. Diagnostic performance of the Gynecology Imaging Reporting and Data System for malignant adnexal masses. *Int J Gynaecol Obstet* 2017; **137**: 325–331.
69. Behnamfar F, Adibi A, Khadra H, Moradi M. Diagnostic accuracy of gynecology imaging reporting and data system in evaluation of adnexal lesions. *J Res Med Sci* 2019; **24**: 57.
70. Migda M, Bartosz M, Migda MS, Kierszk M, Katarzyna G, Malenczyk M. Diagnostic value of the gynecology imaging reporting and data system (GI-RADS) with the ovarian malignancy marker CA-125 in preoperative adnexal tumor assessment. *J Ovarian Res* 2018; **11**: 92.
71. Basha MAA, Refaat R, Ibrahim SA, Madkour NM, Awad AM, Mohamed EM, El Sammak AA, Zaitoun MMA, Dawoud HA, Khamis MEM, Mohamed HAE, El-Maghraby AM, Abdalla A, Assy MM, Nada MG, Obaya AA, Abdelbary EH. Gynecology Imaging Reporting and Data System (GI-RADS): diagnostic performance and inter-reviewer agreement. *Eur Radiol* 2019; **29**: 5981–5990.
72. Andreotti RF, Timmerman D, Benacerraf BR, Bennett GL, Bourne T, Brown DL, Coleman BG, Frates MC, Froyman W, Goldstein SR, Hamper UM, Horrow MM, Hernanz-Schulman M, Reinhold C, Strachowski LM, Glanc P. Ovarian-Adnexal Reporting Lexicon for Ultrasound: A White Paper of the ACR Ovarian-Adnexal Reporting and Data System Committee. *J Am Coll Radiol* 2018; **15**: 1415–1429.
73. Erratum. *J Am Coll Radiol* 2019; **16**: 403–406.
74. Andreotti RF, Timmerman D, Strachowski LM, Froyman W, Benacerraf BR, Bennett GL, Bourne T, Brown DL, Coleman BG, Frates MC, Goldstein SR, Hamper UM, Horrow MM, Hernanz-Schulman M, Reinhold C, Rose SL, Whitcomb BP, Wolfman WL, Glanc P. O-RADS US Risk Stratification and Management System: A Consensus Guideline from the ACR Ovarian-Adnexal Reporting and Data System Committee. *Radiology* 2020; **294**: 168–185.
75. Basha MAA, Metwally MI, Gamil SA, Khater HM, Aly SA, El Sammak AA, Zaitoun MMA, Khattab EM, Azmy TM, Alayouty NA, Mohey N, Almassry HN, Yousef HY, Ibrahim SA, Mohamed EA, Mohamed AEM, Afifi AHM, Harb OA, Algazzar HY. Comparison of O-RADS, GI-RADS, and IOTA simple rules regarding malignancy rate, validity, and reliability for diagnosis of adnexal masses. *Eur Radiol* 2021; **31**: 674–684.
76. Medeiros LR, Rosa DD, da Rosa MI, Bozzetti MC. Accuracy of CA 125 in the diagnosis of ovarian tumors: a quantitative systematic review. *Eur J Obstet Gynecol Reprod Biol* 2009; **142**: 99–105.
77. Babic A, Cramer DW, Kelemen LE, Kobel M, Steed H, Webb PM, Johnatty SE, deFazio A, Lambrechts D, Goodman MT, Heitz F, Matsuo K, Hosono S, Karlan BY, Jensen A, Kjaer SK, Goode EL, Pejovic T, Moffitt M, Hogdall E, Hogdall C, McNeish I, Terry KL. Predictors of pretreatment CA125 at ovarian cancer diagnosis: a pooled analysis in the Ovarian Cancer Association Consortium. *Cancer Causes Control* 2017; **28**: 459–468.
78. Johnson CC, Kessel B, Riley TL, Ragard LR, Williams CR, Xu JL, Buys SS. The epidemiology of CA-125 in women without evidence of ovarian cancer in the Prostate, Lung, Colorectal and Ovarian Cancer (PLCO) Screening Trial. *Gynecol Oncol* 2008; **110**: 383–389.
79. Pauler DK, Menon U, McIntosh M, Symecko HL, Skates SJ, Jacobs IJ. Factors influencing serum CA125II levels in healthy postmenopausal women. *Cancer Epidemiol Biomarkers Prev* 2001; **10**: 489–493.
80. Cramer DW, Vitis AF, Welch WR, Terry KL, Goodman A, Rueda BR, Berkowitz RS. Correlates of the preoperative level of CA125 at presentation of ovarian cancer. *Gynecol Oncol* 2010; **119**: 462–468.
81. Lycke M, Kristjansdottir B, Sundfeldt K. A multicenter clinical trial validating the performance of HE4, CA125, risk of ovarian malignancy algorithm and risk of malignancy index. *Gynecol Oncol* 2018; **151**: 159–165.
82. Lin J, Qin J, Sangvatanakul V. Human epididymis protein 4 for differential diagnosis between benign gynecologic disease and ovarian cancer: a systematic review and meta-analysis. *Eur J Obstet Gynecol Reprod Biol* 2013; **167**: 81–85.
83. Richards A, Herbst U, Manalang J, Pather S, Saidi S, Tejada-Berges T, Tan K, Williams P, Carter J. HE4, CA125, the Risk of Malignancy Algorithm and the Risk of Malignancy Index and complex pelvic masses - a prospective comparison

- in the pre-operative evaluation of pelvic masses in an Australian population. *Aust N Z J Obstet Gynaecol* 2015; 55: 493–497.
84. Romagnolo C, Leon AE, Fabricio ASC, Taborelli M, Polesel J, Del Pup L, Steffan A, Cervo S, Ravaggi A, Zanotti L, Bandiera E, Odicino FE, Scattolo N, Squarcina E, Papadakis C, Maggino T, Gion M. HE4, CA125 and risk of ovarian malignancy algorithm (ROMA) as diagnostic tools for ovarian cancer in patients with a pelvic mass: An Italian multicenter study. *Gynecol Oncol* 2016; 141: 303–311.
  85. Li F, Tie R, Chang K, Wang F, Deng S, Lu W, Yu L, Chen M. Does risk for ovarian malignancy algorithm excel human epididymis protein 4 and CA125 in predicting epithelial ovarian cancer: a meta-analysis. *BMC Cancer* 2012; 12: 258.
  86. Wang J, Gao J, Yao H, Wu Z, Wang M, Qi J. Diagnostic accuracy of serum HE4, CA125 and ROMA in patients with ovarian cancer: a meta-analysis. *Tumour Biol* 2014; 35: 6127–6138.
  87. Van Gorp T, Veldman J, Van Calster B, Cadron I, Leunen K, Amant F, Timmerman D, Vergote I. Subjective assessment by ultrasound is superior to the risk of malignancy index (RMI) or the risk of ovarian malignancy algorithm (ROMA) in discriminating benign from malignant adnexal masses. *Eur J Cancer* 2012; 48: 1649–1656.
  88. Stiekema A, Lok CA, Kenter GG, van Driel WJ, Vincent AD, Korse CM. A predictive model combining human epididymal protein 4 and radiologic features for the diagnosis of ovarian cancer. *Gynecol Oncol* 2014; 132: 573–577.
  89. Yanaranop M, Anakrat V, Siricharoenchai S, Nakrangsee S, Thinkhamrop B. Is the Risk of Ovarian Malignancy Algorithm Better Than Other Tests for Predicting Ovarian Malignancy in Women with Pelvic Masses? *Gynecol Obstet Invest* 2017; 82: 47–53.
  90. Jacob F, Meier M, Caduff R, Goldstein D, Pochechueva T, Hacker N, Fink D, Heinzelmann-Schwarz V. No benefit from combining HE4 and CA125 as ovarian tumor markers in a clinical setting. *Gynecol Oncol* 2011; 121: 487–491.
  91. Melo A, Verissimo R, Farinha M, Martins NN, Martins FN. Discriminative value of CA-125, HE4, Risk of Malignancy Index II (RMI-II) and Risk of Malignancy Algorithm (ROMA) in the differential diagnosis of pelvic masses: conclusions from a referral Centre in Portugal. *J Obstet Gynaecol* 2018; 38: 1140–1145.
  92. Jia MM, Deng J, Cheng XL, Yan Z, Li QC, Xing YY, Fan DM, Tian XY. Diagnostic accuracy of urine HE4 in patients with ovarian cancer: a meta-analysis. *Oncotarget* 2017; 8: 9660–9671.
  93. Huang J, Chen J, Huang Q. Diagnostic value of HE4 in ovarian cancer: A meta-analysis. *Eur J Obstet Gynecol Reprod Biol* 2018; 231: 35–42.
  94. Cao H, You D, Lan Z, Ye H, Hou M, Xi M. Prognostic value of serum and tissue HE4 expression in ovarian cancer: a systematic review with meta-analysis of 90 studies. *Expert Rev Mol Diagn* 2018; 18: 371–383.
  95. Yu S, Yang HJ, Xie SQ, Bao YX. Diagnostic value of HE4 for ovarian cancer: a meta-analysis. *Clin Chem Lab Med* 2012; 50: 1439–1446.
  96. Sandri MT, Bottari F, Franchi D, Boveri S, Candiani M, Ronzoni S, Peiretti M, Radice D, Passerini R, Sideri M. Comparison of HE4, CA125 and ROMA algorithm in women with a pelvic mass: correlation with pathological outcome. *Gynecol Oncol* 2013; 128: 233–238.
  97. Kim B, Park Y, Ahn HJ, Lee KA, Chung JE, Han SW. Diagnostic performance of CA 125, HE4, and risk of Ovarian Malignancy Algorithm for ovarian cancer. *J Clin Lab Anal* 2019; 33: e22624.
  98. Kotowicz B, Fuksiewicz M, Sobiczewski P, Spiewankiewicz B, Jonska-Gmyrek J, Skrzypczak M, Kowalska M. Clinical value of human epididymis protein 4 and the Risk of Ovarian Malignancy Algorithm in differentiating borderline pelvic tumors from epithelial ovarian cancer in early stages. *Eur J Obstet Gynecol Reprod Biol* 2015; 194: 141–146.
  99. Shin KH, Kim HH, Kwon BS, Suh DS, Joo JK, Kim KH. Clinical Usefulness of Cancer Antigen (CA) 125, Human Epididymis 4, and CA72-4 Levels and Risk of Ovarian Malignancy Algorithm Values for Diagnosing Ovarian Tumors in Korean Patients With and Without Endometriosis. *Ann Lab Med* 2020; 40: 40–47.
  100. Terlikowska KM, Dobrzycka B, Witkowska AM, Mackowiak-Matejczyk B, Sledziewski TK, Kinalski M, Terlikowski SJ. Preoperative HE4, CA125 and ROMA in the differential diagnosis of benign and malignant adnexal masses. *J Ovarian Res* 2016; 9: 43.
  101. Xu Y, Zhong R, He J, Ding R, Lin H, Deng Y, Zhou L, Li X, Jiang J, Bao Y, Luo X, Duan C. Modification of cut-off values for HE4, CA125 and the ROMA algorithm for early-stage epithelial ovarian cancer detection: Results from 1021 cases in South China. *Clin Biochem* 2016; 49: 32–40.
  102. Yanaranop M, Jantarateptewan N, Tiyyayon J, Nakrangsee S. Significance of Serum Human Epididymis Protein 4 and Cancer Antigen 125 in Distinguishing Type I and Type II Epithelial Ovarian Cancers. *Int J Gynecol Cancer* 2018; 28: 1058–1065.
  103. Zhang P, Wang C, Cheng L, Guo L, Liu W, Zhang Z, Huang Y, Ou Q, Wen X, Tian Y. Comparison of HE4, CA125, and ROMA Diagnostic Accuracy: A Prospective and Multicenter Study for Chinese Women With Epithelial Ovarian Cancer. *Medicine (Baltimore)* 2015; 94: e2402.
  104. Choi HJ, Lee YY, Sohn I, Kim YM, Kim JW, Kang S, Kim BG. Comparison of CA 125 alone and risk of ovarian malignancy algorithm (ROMA) in patients with adnexal mass: A multicenter study. *Curr Probl Cancer* 2020; 44: 100508.
  105. Kaijser J, Van Gorp T, Smet ME, Van Holsbeke C, Sayasneh A, Epstein E, Bourne T, Vergote I, Van Calster B, Timmerman D. Are serum HE4 or ROMA scores useful to experienced examiners for improving characterization of adnexal masses after transvaginal ultrasonography? *Ultrasound Obstet Gynecol* 2014; 43: 89–97.
  106. Chen X, Zhou H, Chen R, He J, Wang Y, Huang L, Sun L, Duan C, Luo X, Yan H. Development of a multimer assay for differential diagnosis of benign and malignant pelvic masses. *Clin Chim Acta* 2015; 440: 57–63.
  107. Cui R, Wang Y, Li Y. Clinical value of ROMA index in diagnosis of ovarian cancer: meta-analysis. *Cancer Manag Res* 2019; 11: 2545–2551.
  108. Huy NVQ, Van Khoa V, Tam LM, Vinh TQ, Tung NS, Thanh CN, Chuang L. Standard and optimal cut-off values of serum ca-125, HE4 and ROMA in preoperative prediction of ovarian cancer in Vietnam. *Gynecol Oncol Rep* 2018; 25: 110–114.
  109. Shen F, Lu S, Peng Y, Yang F, Chen Y, Lin Y, Yang C, Wu L, Li H, Zheng Y. Performance of ROMA based on Architect CA 125 II and HE4 values in Chinese women presenting with a pelvic mass: A multicenter prospective study. *Clin Chim Acta* 2017; 471: 119–125.
  110. Sagi-Dain L, Lavie O, Auslander R, Sagi S. CEA in evaluation of adnexal mass: retrospective cohort analysis and review of the literature. *Int J Biol Markers* 2015; 30: e394–400.
  111. Sagi-Dain L, Lavie O, Auslander R, Sagi S. CA 19-9 in evaluation of adnexal mass: retrospective cohort analysis and review of the literature. *Int J Biol Markers* 2015; 30: e333–340.
  112. Kelly PJ, Archbold P, Price JH, Cardwell C, McCluggage WG. Serum CA19.9 levels are commonly elevated in primary ovarian mucinous tumours but cannot be used to predict the histological subtype. *J Clin Pathol* 2010; 63: 169–173.
  113. Bozkurt M, Yumru AE, Aral I. Evaluation of the importance of the serum levels of CA-125, CA15-3, CA-19-9, carcinoembryonic antigen and alpha fetoprotein for distinguishing benign and malignant adnexal masses and contribution of different test combinations to diagnostic accuracy. *Eur J Gynaecol Oncol* 2013; 34: 540–544.
  114. Dohan A, Hoeffel C, Soyer P, Jannot AS, Valette PJ, Thivolet A, Passot G, Glehen O, Rousset P. Evaluation of the peritoneal carcinomatosis index with CT and MRI. *Br J Surg* 2017; 104: 1244–1249.
  115. Low RN, Barone RM, Lucero J. Comparison of MRI and CT for predicting the Peritoneal Cancer Index (PCI) preoperatively in patients being considered for cytoreductive surgical procedures. *Ann Surg Oncol* 2015; 22: 1708–1715.
  116. Torkzad MR, Casta N, Bergman A, Ahlstrom H, Pahlman L, Mahteme H. Comparison between MRI and CT in prediction of peritoneal carcinomatosis index (PCI) in patients undergoing cytoreductive surgery in relation to the experience of the radiologist. *J Surg Oncol* 2015; 111: 746–751.
  117. Gadelhak B, Tawfik AM, Saleh GA, Batouty NM, Sobh DM, Hamdy O, Refky B. Extended abdominopelvic MRI versus CT at the time of adnexal mass characterization for assessing radiologic peritoneal cancer index (PCI) prior to cytoreductive surgery. *Abdom Radiol (NY)* 2019; 44: 2254–2261.
  118. Shimada K, Matsumoto K, Mimura T, Ishikawa T, Munechika J, Ohgiya Y, Kushima M, Hirose Y, Asami Y, Iitsuka C, Miyamoto S, Onuki M, Tsunoda H, Matsuoka R, Ichizuka K, Sekizawa A. Ultrasound-based logistic regression model LR2 versus magnetic resonance imaging for discriminating between benign and malignant adnexal masses: a prospective study. *Int J Clin Oncol* 2018; 23: 514–521.
  119. Dai G, Liang K, Xiao Z, Yang Q, Yang S. A meta-analysis on the diagnostic value of diffusion-weighted imaging on ovarian cancer. *J BUON* 2019; 24: 2333–2340.
  120. Meng XF, Zhu SC, Sun SJ, Guo JC, Wang X. Diffusion weighted imaging for the differential diagnosis of benign vs. malignant ovarian neoplasms. *Oncol Lett* 2016; 11: 3795–3802.
  121. Michielsen K, Dresen R, Vanslebrouck R, De Keyzer F, Amant F, Mussen E, Leunen K, Berteloot P, Moerman P, Vergote I, Vandecaveye V. Diagnostic value of whole body diffusion-weighted MRI compared to computed tomography for pre-operative, assessment of patients suspected for ovarian cancer. *Eur J Cancer* 2017; 83: 88–98.
  122. Espada M, Garcia-Flores JR, Jimenez M, Alvarez-Moreno E, De Haro M, Gonzalez-Cortijo L, Hernandez-Cortes G, Martinez-Vega V, Sainz De La Cuesta R. Diffusion-weighted magnetic resonance imaging evaluation of intra-abdominal sites of implants to predict likelihood of suboptimal cytoreductive surgery in patients with ovarian carcinoma. *Eur Radiol* 2013; 23: 2636–2642.
  123. Rizzo S, De Piano F, Buscarino V, Pagan E, Bagnardi V, Zaganolo V, Colombo N, Maggioni A, Del Grande M, Del Grande F, Bellomi M, Aletti G. Pre-operative evaluation of epithelial ovarian cancer patients: Role of whole body diffusion weighted imaging MR and CT scans in the selection of patients suitable for primary debulking surgery. A single-centre study. *Eur J Radiol* 2020; 123: 108786.
  124. Gity M, Parviz S, Saligheh Rad H, Fathi Kazerooni A, Shirali E, Shakiba M, Baikpour M. Differentiation of Benign from Malignant Adnexal Masses by Dynamic Contrast-Enhanced MRI (DCE-MRI): Quantitative and Semi-quantitative analysis at 3-Tesla MRI. *Asian Pac J Cancer Prev* 2019; 20: 1073–1079.
  125. Malek M, Oghabian Z, Tabibian E, Rahmani M, Miratashi Yazdi SN, Oghabian MA, Parviz S. Comparison of Qualitative (Time Intensity Curve Analysis), Semi-Quantitative, and Quantitative Multi-Phase 3T DCEMRI Parameters as Predictors of Malignancy in Adnexal. *Asian Pac J Cancer Prev* 2019; 20: 1603–1611.
  126. Thomassin-Naggara I, Balvay D, Aubert E, Darai E, Rouzier R, Cuenod CA, Bazot M. Quantitative dynamic contrast-enhanced MR imaging analysis of complex adnexal masses: a preliminary study. *Eur Radiol* 2012; 22: 738–745.
  127. Carter JS, Koopmeiners JS, Kuehn-Hajder JE, Metzger GJ, Lakkadi N, Downs LS Jr, Bolan PJ. Quantitative multiparametric MRI of ovarian cancer. *J Magn Reson Imaging* 2013; 38: 1501–1509.
  128. He M, Song Y, Li H, Lu J, Li Y, Duan S, Qiang J. Histogram Analysis Comparison of Monoexponential, Advanced Diffusion-Weighted Imaging, and Dynamic Contrast-Enhanced MRI for Differentiating Borderline From Malignant Epithelial Ovarian Tumors. *J Magn Reson Imaging* 2020; 52: 257–268.
  129. Li HM, Feng F, Qiang JW, Zhang GF, Zhao SH, Ma FH, Li YA, Gu WY. Quantitative dynamic contrast-enhanced MR imaging for differentiating benign, borderline, and malignant ovarian tumors. *Abdom Radiol (NY)* 2018; 43: 3132–3141.
  130. Thomassin-Naggara I, Poncelet E, Jalaguier-Coudray A, Guerra A, Fournier LS, Stojanovic S, Millet I, Bharwani N, Juhan V, Cunha TM, Masselli G, Balleyguier C, Malhaire C, Perrot NF, Sadowski EA, Bazot M, Taourel P, Porcher R, Darai E, Reinhold C, Rockall AG. Ovarian-Adnexal Reporting Data System Magnetic Resonance Imaging (O-RADS MRI) Score for Risk Stratification of Sonographically Indeterminate Adnexal Masses. *JAMA Netw Open* 2020; 3: e1919896.
  131. Dirrichs T, Bauerschlag D, Maass N, Kuhl CK, Schrading S. Impact of Multiparametric MRI (mMRI) on the Therapeutic Management of Adnexal Masses Detected with Transvaginal Ultrasound (TVUS): An Interdisciplinary Management

- Approach. *Acad Radiol* 2020; **S1076-6332(20)30652-8**. DOI: 10.1016/j.acra.2020.11.016.
132. Ahmed SA, Abou-Taleb H, Yehia A, El Malek NAA, Siefeldein GS, Badary DM, Jabir MA. The accuracy of multi-detector computed tomography and laparoscopy in the prediction of peritoneal carcinomatosis index score in primary ovarian cancer. *Acad Radiol* 2019; **26**: 1650–1658.
  133. Byrom J, Widjaja E, Redman CW, Jones PW, Tebby S. Can pre-operative computed tomography predict resectability of ovarian carcinoma at primary laparotomy? *BJOG* 2002; **109**: 369–375.
  134. Esquivel J, Chua TC, Stojadinovic A, Melero JT, Levine EA, Gutman M, Howard R, Piso P, Nissan A, Gomez-Portilla A, Gonzalez-Bayon L, Gonzalez-Moreno S, Shen P, Stewart JH, Sugarbaker PH, Barone RM, Hoefler R, Morris DL, Sardi A, Sticca RP. Accuracy and clinical relevance of computed tomography scan interpretation of peritoneal cancer index in colorectal cancer peritoneal carcinomatosis: a multi-institutional study. *J Surg Oncol* 2010; **102**: 565–570.
  135. Marin D, Catalano C, Baski M, Di Martino M, Geiger D, Di Giorgio A, Sibio S, Passariello R. 64-Section multi-detector row CT in the preoperative diagnosis of peritoneal carcinomatosis: correlation with histopathological findings. *Abdom Imaging* 2010; **35**: 694–700.
  136. Nasser S, Lazaridis A, Evangelou M, Jones B, Nixon K, Kyrgiou M, Gabra H, Rockall A, Fotopoulou C. Correlation of pre-operative CT findings with surgical & histological tumor dissemination patterns at cytoreduction for primary advanced and relapsed epithelial ovarian cancer: A retrospective evaluation. *Gynecol Oncol* 2016; **143**: 264–269.
  137. Avesani G, Arshad M, Lu H, Fotopoulou C, Cannone F, Melotti R, Aboagye E, Rockall A. Radiological assessment of Peritoneal Cancer Index on preoperative CT in ovarian cancer is related to surgical outcome and survival. *Radiol Med* 2020; **125**: 770–776.
  138. Shim SH, Lee SJ, Kim SO, Kim SN, Kim DY, Lee JJ, Kim JH, Kim YM, Kim YT, Nam JH. Nomogram for predicting incomplete cytoreduction in advanced ovarian cancer patients. *Gynecol Oncol* 2015; **136**: 30–36.
  139. Dowdy SC, Mullany SA, Brandt KR, Huppert BJ, Cliby WA. The utility of computed tomography scans in predicting suboptimal cytoreductive surgery in women with advanced ovarian carcinoma. *Cancer* 2004; **101**: 346–352.
  140. Nelson BE, Rosenfield AT, Schwartz PE. Preoperative abdominopelvic computed tomographic prediction of optimal cytoreduction in epithelial ovarian carcinoma. *J Clin Oncol* 1993; **11**: 166–172.
  141. Bristow RE, Duska LR, Lambrou NC, Fishman EK, O'Neill MJ, Trimble EL, Montz FJ. A model for predicting surgical outcome in patients with advanced ovarian carcinoma using computed tomography. *Cancer* 2000; **89**: 1532–1540.
  142. Gemer O, Galevich M, Ravid M, Piura B, Rabinovich A, Gasper T, Khashper A, Voldarsky M, Linov L, Ben Shachar I, Anteby EY, Lavie O. A multicenter validation of computerized tomography models as predictors of non-optimal primary cytoreduction of advanced epithelial ovarian cancer. *Eur J Surg Oncol* 2009; **35**: 1109–1112.
  143. Axtell AE, Lee MH, Bristow RE, Dowdy SC, Cliby WA, Raman S, Weaver JP, Gabbay M, Ngo M, Lentz S, Cass I, Li AJ, Karlan BY, Holschneider CH. Multi-institutional reciprocal validation study of computed tomography predictors of suboptimal primary cytoreduction in patients with advanced ovarian cancer. *J Clin Oncol* 2007; **25**: 384–389.
  144. Rutten MJ, van de Vrie R, Bruining A, Spijkerboer AM, Mol BW, Kenter GG, Buist MR. Predicting surgical outcome in patients with International Federation of Gynecology and Obstetrics stage III or IV ovarian cancer using computed tomography: a systematic review of prediction models. *Int J Gynecol Cancer* 2015; **25**: 407–415.
  145. Kim HJ, Choi CH, Lee YY, Kim TJ, Lee JW, Bae DS, Kim BG. Surgical outcome prediction in patients with advanced ovarian cancer using computed tomography scans and intraoperative findings. *Taiwan J Obstet Gynecol* 2014; **53**: 343–347.
  146. Lu H, Arshad M, Thornton A, Avesani G, Cunnea P, Curry E, Kanavati F, Liang J, Nixon K, Williams ST, Hassan MA, Bowtell DDL, Gabra H, Fotopoulou C, Rockall A, Aboagye EO. A mathematical-descriptor of tumor-mesoscopic-structure from computed-tomography images annotates prognostic- and molecular-phenotypes of epithelial ovarian cancer. *Nat Commun* 2019; **10**: 764.
  147. Tanizaki Y, Kobayashi A, Shiro M, Ota N, Takano R, Mabuchi Y, Yagi S, Minami S, Terada M, Ino K. Diagnostic value of preoperative SUVmax on FDG-PET/CT for the detection of ovarian cancer. *Int J Gynecol Cancer* 2014; **24**: 454–460.
  148. Kitajima K, Suzuki K, Senda M, Kita M, Nakamoto Y, Onishi Y, Maeda T, Yoshikawa T, Ohno Y, Sugimura K. FDG-PET/CT for diagnosis of primary ovarian cancer. *Nucl Med Commun* 2011; **32**: 549–553.
  149. Nam EJ, Yun MJ, Oh YT, Kim JW, Kim JH, Kim S, Jung YW, Kim SW, Kim YT. Diagnosis and staging of primary ovarian cancer: correlation between PET/CT, Doppler US, and CT or MRI. *Gynecol Oncol* 2010; **116**: 389–394.
  150. Castellucci P, Perrone AM, Picchio M, Ghi T, Farsad M, Nanni C, Messa C, Meriggola MC, Pelusi G, Al-Nahhas A, Rubello D, Fazio F, Fanti S. Diagnostic accuracy of 18F-FDG PET/CT in characterizing ovarian lesions and staging ovarian cancer: correlation with transvaginal ultrasonography, computed tomography, and histology. *Nucl Med Commun* 2007; **28**: 589–595.
  151. Risum S, Hogdall C, Loft A, Berthelsen AK, Hogdall E, Nedergaard L, Lundvall L, Engelholm SA. The diagnostic value of PET/CT for primary ovarian cancer—a prospective study. *Gynecol Oncol* 2007; **105**: 145–149.
  152. Yamamoto Y, Oguri H, Yamada R, Maeda N, Kohsaki S, Fukaya T. Preoperative evaluation of pelvic masses with combined 18F-fluorodeoxyglucose positron emission tomography and computed tomography. *Int J Gynaecol Obstet* 2008; **102**: 124–127.
  153. Dauwen H, Van Calster B, Deroose CM, Op de Beeck K, Amant F, Neven P, Berteloot P, Leunen K, Timmerman D, Vergote I. PET/CT in the staging of patients with a pelvic mass suspicious for ovarian cancer. *Gynecol Oncol* 2013; **131**: 694–700.
  154. Laghi A, Bellini D, Rengo M, Accarpio F, Caruso D, Biacchi D, Di Giorgio A, Sammartino P. Diagnostic performance of computed tomography and magnetic resonance imaging for detecting peritoneal metastases: systematic review and meta-analysis. *Radiol Med* 2017; **122**: 1–15.
  155. Kim SJ, Lee SW. Diagnostic accuracy of (18)F-FDG PET/CT for detection of peritoneal carcinomatosis; a systematic review and meta-analysis. *Br J Radiol* 2018; **91**: 20170519.
  156. Michielsens K, Vergote I, Op de Beeck K, Amant F, Leunen K, Moerman P, Deroose C, Souverijns G, Dymarkowski S, De Keyzer F, Vandecaveye V. Whole-body MRI with diffusion-weighted sequence for staging of patients with suspected ovarian cancer: a clinical feasibility study in comparison to CT and FDG-PET/CT. *Eur Radiol* 2014; **24**: 889–901.
  157. Barbosa A, Peixoto A, Pinto P, Pinheiro M, Teixeira MR. Potential clinical applications of circulating cell-free DNA in ovarian cancer patients. *Expert Rev Mol Med* 2018; **20**: e6.
  158. Chen Q, Zhang ZH, Wang S, Lang JH. Circulating Cell-Free DNA or Circulating Tumor DNA in the Management of Ovarian and Endometrial Cancer. *Oncol Targets Ther* 2019; **12**: 11517–11530.
  159. Giannopoulou L, Kasimir-Bauer S, Lianidou ES. Liquid biopsy in ovarian cancer: recent advances on circulating tumor cells and circulating tumor DNA. *Clin Chem Lab Med* 2018; **56**: 186–197.
  160. Widschwendter M, Zikan M, Wahl B, Lempiainen H, Paprotka T, Evans I, Jones A, Ghazali S, Reisel D, Eichner J, Rujan T, Yang Z, Teschendorff AE, Ryan A, Cibula D, Menon U, Wittenberger T. The potential of circulating tumor DNA methylation analysis for the early detection and management of ovarian cancer. *Genome Med* 2017; **9**: 116.
  161. Guo YX, Neoh KH, Chang XH, Sun Y, Cheng HY, Ye X, Ma RQ, Han RPS, Cui H. Diagnostic value of HE4+ circulating tumor cells in patients with suspicious ovarian cancer. *Oncotarget* 2018; **9**: 7522–7533.
  162. Kolostova K, Matkowski R, Jedryka M, Soter K, Cegan M, Pinkas M, Jakubova A, Pavlasek J, Spicka J, Bobek V. The added value of circulating tumor cells examination in ovarian cancer staging. *Am J Cancer Res* 2015; **5**: 3363–3375.
  163. Li B, Pu K, Ge L, Wu X. Diagnostic significance assessment of the circulating cell-free DNA in ovarian cancer: An updated meta-analysis. *Gene* 2019; **714**: 143993.
  164. Li N, Zuo H, Chen L, Liu H, Zhou J, Yao Y, Xu B, Gong H, Weng Y, Hu Q, Song Q, Peng M, Cheng Y. Circulating Tumor Cell Detection In Epithelial Ovarian Cancer Using Dual-Component Antibodies Targeting EpCAM And FRalpha. *Cancer Manag Res* 2019; **11**: 10939–10948.
  165. Lou E, Vogel RI, Teoh D, Hoostal S, Grad A, Gerber M, Monu M, Lukaszewski T, Deshpande J, Linden MA, Geller MA. Assessment of Circulating Tumor Cells as a Predictive Biomarker of Histology in Women With Suspected Ovarian Cancer. *Lab Med* 2018; **49**: 134–139.
  166. Phallen J, Sausen M, Adleff V, Leal A, Hruban C, White J, Anagnostou V, Fiksel J, Cristiano S, Papp E, Speir S, Reinert T, Orntoft MW, Woodward BD, Murphy D, Parnpart-Li S, Riley D, Nesselbush M, Sengamalai N, Georgiadis A, Li QK, Madsen MR, Mortensen FV, Huiskens J, Punt C, van Grieken N, Fijneman R, Meijer G, Husain H, Scharpf RB, Diaz LA, Jr., Jones S, Angiuoli S, Orntoft T, Nielsen HJ, Andersen CL, Velculescu VE. Direct detection of early-stage cancers using circulating tumor DNA. *Sci Transl Med* 2017; **9**: eaa2415.
  167. Suh DH, Kim M, Choi JY, Bu J, Kang YT, Kwon BS, Lee B, Kim K, No JH, Kim YB, Cho YH. Circulating tumor cells in the differential diagnosis of adnexal masses. *Oncotarget* 2017; **8**: 77195–77206.
  168. Vanderstichele A, Busschaert P, Smeets D, Landolfo C, Van Nieuwenhuysen E, Leunen K, Neven P, Amant F, Mahner E, Braicu EI, Zeilinger R, Coosemans A, Timmerman D, Lambrechts D, Vergote I. Chromosomal Instability in Cell-Free DNA as a Highly Specific Biomarker for Detection of Ovarian Cancer in Women with Adnexal Masses. *Clin Cancer Res* 2017; **23**: 2223–2231.
  169. Yu Z, Qin S, Wang H. Alter circulating cell-free DNA variables in plasma of ovarian cancer patients. *J Obstet Gynaecol Res* 2019; **45**: 2237–2242.
  170. Zhou Q, Li W, Leng B, Zheng W, He Z, Zuo M, Chen A. Circulating Cell Free DNA as the Diagnostic Marker for Ovarian Cancer: A Systematic Review and Meta-Analysis. *PLoS One* 2016; **11**: e0155495.
  171. Van Holsbeke C, Van Calster B, Guerriero S, Savelli L, Paladini D, Lissoni AA, Czekirowski A, Fischerova D, Zhang J, Mestdagh G, Testa AC, Bourne T, Valentin L, Timmerman D. Endometriomas: their ultrasound characteristics. *Ultrasound Obstet Gynecol* 2010; **35**: 730–740.
  172. Paladini D, Testa A, Van Holsbeke C, Mancari R, Timmerman D, Valentin L. Imaging in gynecological disease (5): clinical and ultrasound characteristics in fibroma and fibrothecoma of the ovary. *Ultrasound Obstet Gynecol* 2009; **34**: 188–195.
  173. Demidov VN, Lipatenkova J, Vikhareva O, Van Holsbeke C, Timmerman D, Valentin L. Imaging of gynecological disease (2): clinical and ultrasound characteristics of Sertoli cell tumors, Sertoli-Leydig cell tumors and Leydig cell tumors. *Ultrasound Obstet Gynecol* 2008; **31**: 85–91.
  174. Savelli L, Testa AC, Timmerman D, Paladini D, Ljungberg O, Valentin L. Imaging of gynecological disease (4): clinical and ultrasound characteristics of struma ovarii. *Ultrasound Obstet Gynecol* 2008; **32**: 210–219.
  175. Virgilio BA, De Blasis I, Sladkevicius P, Moro F, Zannoni GF, Arciuolo D, Mascilini F, Ciccarone F, Timmerman D, Kaijser J, Fruscio R, Van Holsbeke C, Franchi D, Epstein E, Leone FPG, Guerriero S, Czekirowski A, Scambia G, Testa AC, Valentin L. Imaging in gynecological disease (16): clinical and ultrasound characteristics of serous cystadenofibromas in adnexa. *Ultrasound Obstet Gynecol* 2019; **54**: 823–830.
  176. Moro F, Zannoni GF, Arciuolo D, Pasciuto T, Amoroso S, Mascilini F, Mainenti S, Scambia G, Testa AC. Imaging in gynecological disease (11): clinical and ultrasound features of mucinous ovarian tumors. *Ultrasound Obstet Gynecol* 2017; **50**: 261–270.
  177. Dierickx I, Valentin L, Van Holsbeke C, Jacomen G, Lissoni AA, Licameli A, Testa A, Bourne T, Timmerman D. Imaging in gynecological disease (7): clinical

- and ultrasound features of Brenner tumors of the ovary. *Ultrasound Obstet Gynecol* 2012; 40: 706–713.
178. Timor-Tritsch IE, Lerner JP, Monteagudo A, Murphy KE, Heller DS. Transvaginal sonographic markers of tubal inflammatory disease. *Ultrasound Obstet Gynecol* 1998; 12: 56–66.
  179. Franchi D, Boveri S, Fruscio R, Fischerova D, Guerriero S, Moruzzi MC, Colombo N, Timmerman D, Valentin L, Testa AC. Imaging in gynecological disease (8): ultrasound characteristics of recurrent borderline ovarian tumors. *Ultrasound Obstet Gynecol* 2013; 41: 452–458.
  180. Moro F, Baima Poma C, Zannoni GF, Vidal Urbinati A, Pasciuto T, Ludovisi M, Moruzzi MC, Carinelli S, Franchi D, Scambia G, Testa AC. Imaging in gynecological disease (12): clinical and ultrasound features of invasive and non-invasive malignant serous ovarian tumors. *Ultrasound Obstet Gynecol* 2017; 50: 788–799.
  181. Landolfo C, Valentin L, Franchi D, Van Holsbeke C, Fruscio R, Froyman W, Sladkevicius P, Kaijser J, Ameye L, Bourne T, Savelli L, Coosemans A, Testa A, Timmerman D. Differences in ultrasound features of papillations in unilocular-solid adnexal cysts: a retrospective international multicenter study. *Ultrasound Obstet Gynecol* 2018; 52: 269–278.
  182. Kurman RJ, Carcangiu ML, Herrington S, Young RH (eds). WHO Classification of Tumours of Female Reproductive Organs, 4th edn. IARC: Lyon, 2014.
  183. Moro F, Magoga G, Pasciuto T, Mascilini F, Moruzzi MC, Fischerova D, Savelli L, Giunchi S, Mancari R, Franchi D, Czekierdowski A, Froyman W, Verri D, Epstein E, Chiappa V, Guerriero S, Zannoni GF, Timmerman D, Scambia G, Valentin L, Testa AC. Imaging in gynecological disease (13): clinical and ultrasound characteristics of endometrioid ovarian cancer. *Ultrasound Obstet Gynecol* 2018; 52: 535–543.
  184. Pozzati F, Moro F, Pasciuto T, Gallo C, Ciccarone F, Franchi D, Mancari R, Giunchi S, Timmerman D, Landolfo C, Epstein E, Chiappa V, Fischerova D, Fruscio R, Zannoni GF, Valentin L, Scambia G, Testa AC. Imaging in gynecological disease (14): clinical and ultrasound characteristics of ovarian clear cell carcinoma. *Ultrasound Obstet Gynecol* 2018; 52: 792–800.
  185. Van Holsbeke C, Domali E, Holland TK, Achten R, Testa AC, Valentin L, Jurkovic D, Moerman P, Timmerman D. Imaging of gynecological disease (3): clinical and ultrasound characteristics of granulosa cell tumors of the ovary. *Ultrasound Obstet Gynecol* 2008; 31: 450–456.
  186. Guerriero S, Testa AC, Timmerman D, Van Holsbeke C, Ajossa S, Fischerova D, Franchi D, Leone FP, Domali E, Alcazar JL, Parodo G, Mascilini F, Virgilio B, Demidov VN, Lipatenkova J, Valentin L. Imaging of gynecological disease (6): clinical and ultrasound characteristics of ovarian dysgerminoma. *Ultrasound Obstet Gynecol* 2011; 37: 596–602.
  187. Anfelter P, Testa A, Chiappa V, Froyman W, Fruscio R, Guerriero S, Alcazar JL, Mascilini F, Pascual MA, Sibal M, Savelli L, Zannoni GF, Timmerman D, Epstein E. Imaging in gynecological disease (17): ultrasound features of malignant ovarian yolk sac tumors (endodermal sinus tumors). *Ultrasound Obstet Gynecol* 2020; 56: 276–284.
  188. Corrigendum. *Ultrasound Obstet Gynecol* 2020; 56: 966. DOI: 10.1002/uog.23526.
  189. Moro F, Castellano LM, Franchi D, Epstein E, Fischerova D, Froyman W, Timmerman D, Zannoni GF, Scambia G, Valentin L, Testa AC, Mascilini F. Imaging in gynecological disease: clinical and ultrasound characteristics of ovarian embryonal carcinomas, non-gestational choriocarcinomas and malignant mixed germ cell tumors. *Ultrasound Obstet Gynecol* 2020. DOI: 10.1002/uog.23529.
  190. Testa AC, Ferrandina G, Timmerman D, Savelli L, Ludovisi M, Van Holsbeke C, Malaggesi M, Scambia G, Valentin L. Imaging in gynecological disease (1): ultrasound features of metastases in the ovaries differ depending on the origin of the primary tumor. *Ultrasound Obstet Gynecol* 2007; 29: 505–511.
  191. Ludovisi M, De Blasis I, Virgilio B, Fischerova D, Franchi D, Pascual MA, Savelli L, Epstein E, Van Holsbeke C, Guerriero S, Czekierdowski A, Zannoni G, Scambia G, Jurkovic D, Rossi A, Timmerman D, Valentin L, Testa AC. Imaging in gynecological disease (9): clinical and ultrasound characteristics of tubal cancer. *Ultrasound Obstet Gynecol* 2014; 43: 328–335.

## APPENDICES

### Appendix 1 Identification of scientific evidence: literature search in MEDLINE

#### Research period

1 May 2015–1 May 2020

#### Indexing terms

adnexal masses, alpha fetoprotein, assessment of different neoplasias in the adnexa, assessment of different neoplasias in the adnexa masses, assessment of different neoplasias in the adnexa model, benign ovarian masses, benign ovarian tumours, beta-human chorionic gonadotropin, biomarker, borderline tumours, carbohydrate antigen 19.9, carbohydrate antigen 125, carcinoembryonic antigen, cell-free deoxyribonucleic acid, circulating cancer cells, circulating cell-free deoxyribonucleic acid, circulating free deoxyribonucleic acid, circulating tumour cells, circulating tumour deoxyribonucleic acid, clinical routine, computed tomography, consensus statement, daily practice, diagnosis, diagnostic performance, diagnostic models, diffusion-weighted imaging, diffusion-weighted magnetic resonance imaging, dynamic contrast-enhanced magnetic resonance imaging, expert ultrasound examiners, first line test, functional sequences, gynecology imaging reporting and data system, human epididymis protein, imaging, imaging methods, immunohistochemical diagnosis, inhibin, international ovarian tumor analysis, international ovarian tumor analysis methods, international ovarian tumor analysis rules, intraoperative ultrasound, investigations, logistic regression 1 test, logistic regression 2 test, magnetic resonance imaging, malignant ovarian masses, malignant ovarian tumours, marker, maximum standardized uptake value, molecular biology, molecular marker, morphological scoring system, multivariate analysis, ovarian cancer, ovarian masses, ovarian tumours, ovary, positron emission tomography, positron emission tomography-computed tomography, pre-operative characterization, pre-operative diagnosis, prognostic factor, prognostic value, protein biomarker, risk factors, risk of malignancy score, risk of malignancy index, risk of ovarian malignancy algorithm, scoring system, screening test, secondary metastatic tumours, second line test, simple rules, simple rules risk, simple rules risk model, single protein biomarker, standardized uptake value, suspected malignancy, suspected metastatic tumour, test performances, threshold risk, transabdominal ultrasound, transvaginal ultrasound, tumour markers, ultrasonography, ultrasound, ultrasound (3D), ultrasound-based diagnostic models, ultrasound-based risk models, ultrasound examiners, vascular endothelial growth factor, vascular endothelial growth factor, whole body diffusion magnetic resonance imaging.

#### Language

English

#### Study design

Priority was given to high-quality systematic reviews, meta-analyses and validating cohort studies, but lower levels of evidence were also evaluated. Search strategy excluded editorials, letters and case reports. Reference list of each identified article was reviewed for other potentially relevant papers.

## Appendix 2 Levels of evidence and grades of statement used in this Consensus Statement

Levels of evidence		
1a	Systematic review (with homogeneity) of Level-1 diagnostic studies; or clinical decision rule with Level-1b studies from different clinical centers	
1b	Validating cohort study with good reference standards; or clinical decision rule tested within one clinical center	
1c	Absolute SpPins and SnNouts*	
2a	Systematic review (with homogeneity) of Level > 2 diagnostic studies	
2b	Exploratory cohort study with good reference standards; or clinical decision rule after derivation, or validated only on split-sample or databases	
3a	Systematic review (with homogeneity) of studies Level $\geq$ 3b	
3b	Non-consecutive study; or without consistently applied reference standards	
4	Case-control study, poor or non-independent reference standard	
5	Expert opinion without explicit critical appraisal, or based on physiology, bench research or 'first principles'	
Grades of statement		
Code	Quality of evidence	Definition
A	High	Further research is very unlikely to change our confidence in the estimate of effect. <ul style="list-style-type: none"> <li>• Several high-quality studies with consistent results</li> <li>• In special cases: one large, high-quality multicenter trial</li> </ul>
B	Moderate	Further research is likely to have an important impact on our confidence in the estimate of effect and may change the estimate. <ul style="list-style-type: none"> <li>• One high-quality study</li> <li>• Several studies with some limitations</li> </ul>
C	Low	Further research is very likely to have an important impact on our confidence in the estimate of effect and is likely to change the estimate. <ul style="list-style-type: none"> <li>• One or more studies with severe limitations</li> </ul>
D	Very low	Any estimate of effect is very uncertain. <ul style="list-style-type: none"> <li>• Expert opinion</li> <li>• No direct research evidence</li> <li>• One or more studies with very severe limitations</li> </ul>

Note: A minus sign '-' may be added to denote evidence that fails to provide a conclusive answer because it is *either* (a) a single result with a wide confidence interval; *or* (b) a systematic review with considerable heterogeneity. Such evidence is inconclusive, and therefore can only generate Grade D recommendations.

\*'Absolute SpPin' is a diagnostic finding whose specificity is so high that a positive result rules in the diagnosis; 'Absolute SnNout' is a diagnostic finding whose sensitivity is so high that a negative result rules out the diagnosis.